

# A novel therapeutic combination of vildagliptin and agomelatine alleviates the nephropathy in streptozocin-induced diabetic rats: A structural & biochemical study

OSAMA I. RAMADAN<sup>1\*</sup>, AHMED A. DAMANHORY<sup>2,3</sup>, EZZ-ELDIN E. ABD-ALLAH<sup>1</sup>, TAMER A. GOMAH<sup>1</sup>, MOHAMMED E. MAHMOUD<sup>1</sup>, FATMA M. ABD-ALLAH<sup>1</sup>, HAITHAM M. SEWILAM<sup>4</sup>, REDA M.A. FAYYAD<sup>5,6</sup>, MEDHAT M. DARWISH<sup>7</sup>, FAHAID AL-HASHEM<sup>8</sup>, MOAAZ M.Y. AWAD<sup>9,10</sup>, MAHMOUD DIAB<sup>11,12</sup>, TAYEE, E. M<sup>13</sup>, MAGDY Y. ELSEED<sup>14</sup>, ALSAYED A. ABDEL HADY<sup>15</sup>, ABDELHAMID K. ELSIFY<sup>16,17</sup>.

<sup>1</sup>Histology Department, Damietta Faculty of Medicine, Al-Azhar University, Egypt.

<sup>2</sup>Department of Biochemistry, Medicine Program, Batterjee Medical College, Jeddah, KSA.

<sup>3</sup>Department of Biochemistry, Faculty of Medicine, Al-Azhar University, Cairo, Egypt.

<sup>4</sup>Histology Department, Faculty of Medicine, Helwan University, Egypt.

<sup>5</sup>Pharmacology Department, Faculty of Medicine, Al-Azhar University, Cairo, Egypt.

<sup>6</sup>Pharmacology Department, Batterjee Medical College, KSA.

<sup>7</sup>Department of Medical Biochemistry, Damietta Faculty of Medicine, Al-Azhar University, Egypt.

<sup>8</sup>Department of Physiology, College of Medicine, King Khalid University, Abha, Saudi Arabia.

<sup>9</sup>Anatomy and Embryology Department, Damietta Faculty of Medicine, Al-Azhar University, Egypt.

<sup>10</sup>Anatomy Department, Batterjee Medical College, KSA.

<sup>11</sup>Anatomy Department, Faculty of Medicine, Al-Azhar University, Cairo, Egypt.

<sup>12</sup>Anatomy Department, Faculty of applied medical sciences, University of Tabuk, KSA.

<sup>13</sup>Clinical pharmacology Department, Faculty of Medicine, Helwan University, Egypt.

<sup>14</sup>Department of Physiology, Damietta Faculty of Medicine, Al-Azhar University, Egypt.

<sup>15</sup>Anatomy Department, Faculty of Medicine, Helwan University, Egypt.

<sup>16</sup>Anatomy Department, Faculty of Medicine, Ain Shams University, Egypt.

<sup>17</sup>Anatomy Department, Batterjee Medical College, KSA.

\* Corresponding Author. E-mail: dr.osama784@yahoo.com; Tel. 002- 01065809014.

Received: 26 February 2023 / Revised: 0 Month 202X / Accepted: 0 Month 202X

**Abstract:** Diabetes mellitus is a worldwide epidemic causes numerous health problems including nephropathy and depression which are caused by oxygen radicals. We investigated the antioxidative effects of agomelatine or vildagliptin on streptozotocin-induced diabetic nephropathy in rats. 50 male albino rats were distributed into five groups, (n = 10/group): the normal control, A single intraperitoneal injection of streptozotocin was given to the other four groups to induce diabetes at a dose of 60 mg/kg body weight. After diabetes induction, one of the groups was chosen as a positive control. Other rats were treated with either vildagliptin (10 mg/kg) and/or agomelatine (20 mg/kg/day) daily for 4 weeks. We used different biochemical parameters (blood glucose level, insulin levels, oxidative stress markers) as well as histological analysis on the kidney tissues of the experimental animals. Statistical evaluation was performed by One-way ANOVA for comparison of those groups followed by Duncan's post hoc test for multiple group comparison. Diabetes induced nephropathy via oxidative pathway as this was confirmed by increased serum levels of urea, uric acid and creatinine with decrease in serum total antioxidant Capacity (TAC) in diabetic rats compared to control rats. Also, there were significant increase in renal levels of malondialdehyde (MDA) and nitric oxide (NO); significant decrease in the levels of renal glutathione (GSH) and superoxide dismutase (SOD) in diabetic group compared to the control group. Administration of either vildagliptin and/or agomelatine or both to diabetic rats alleviated the previous indices as confirmed by the biochemical and histological changes with better improvement in (vildagliptin+agomelatine) to that of vildagliptin treatment alone. **Conclusion:** Combination of agomelatine and vildagliptin could ameliorate diabetic nephropathy through inhibition of oxidative stress.

**Keywords:** Antidepressant; Agomelatine; Diabetic nephropathy, Streptozotocin; Vildagliptin.

**How to cite this article:** Ramadan OI, Damanhory AA, Abd-allah EE, Gomah TA, Mahmoud ME, Abd-allah FM, Sewilam HM, Fayyad RM, Darwish MM, Al-hashem F, Awad MM, Diab M, Tayee EM, Elseed MY, Abdel hady AA, Elsify AK. A novel therapeutic combination of vildagliptin and agomelatine alleviates the nephropathy in streptozotocin-induced diabetic rats: structural & biochemical study. J Res Pharm. 2024; 28(4): 1316-1330.

## 1. INTRODUCTION

Diabetes mellitus (DM), is a metabolic disorder characterized by chronic hyperglycemia resulting from deficiencies in insulin secretion and the lack of effective treatments of diabetes mellitus may result in a serious microvascular complication called diabetic nephropathy (DN), which has a high mortality rate [1, 2].

High blood glucose levels have been linked to kidney disorders through varieties of mechanisms, including the buildup of advanced glycation end products, abnormal production of certain growth factors and cytokines, and complex hemodynamic or endocrine system dysfunctions. These mechanisms may then trigger oxidative stress, a persistent inflammatory response, and ineffective apoptosis, which in turn causes persistent proteinuria and lowers estimated glomerular filtrate [3].

The oxidative stress caused by chronic hyperglycemia results in decrease in glomerular filtration rate (GFR) and an inflammatory response in the kidney. Also, it causes glomerulosclerosis and podocyte destruction, and altering the kidney's histological structure. [4]. Moreover that, depression is frequently experienced by diabetic patients, and there is a strong correlation between the degree of depression and the occurrence of diabetes complications, particularly diabetic nephropathy [5].

Vildagliptin, an antidiabetic drug, is a dipeptidyl peptidase-4 (DPP-4) inhibitor that increases glucagon-like peptide-1 (GLP-1) levels through its antioxidant, antiinflammatory, antifibrotic, and antiapoptotic actions [6]. There are few researches examining the nephroprotective effect of antihyperglycemic medications in metabolic disorders, as a part of their glucose-lowering action [7].

Although kidney damage caused by diabetic nephropathy can now be slowed down with therapeutic drugs, it cannot be reversed or improved [8]. Antioxidant therapy is known to be a significant treatment option for the prevention of diabetic complications and reduction of tissue damage [9].

The pineal gland and a few other organs secrete the melatonin hormone. It decreases lipid peroxidation and has a powerful antioxidant effect [3]. Melatonin may help in management of diabetes through regulation of glucose metabolism and oxidative stress and playing a role in protecting the kidney, alleviating the symptoms of glomerular disorders in their early stages [10].

Agomelatine is a synthetic melatonin agonist that has been used in preclinical and clinical researches to treat neuropathic pain caused by diabetes as well as to treat depression [11]. The peak of endogenous melatonin release is amplified by agomelatine administration [12]. There are only few researches on agomelatine's antidiabetic properties, although there is a lot of evidence that melatonin and glucose homeostasis interact closely. As a melatonergic receptor agonist, agomelatine has been expected to have similar effects of melatonin on glucose homeostasis [13].

Agomelatine and vildagliptin could collaborate to treat diabetic nephropathy because of the possible synergism of their antioxidative effects, however no previous study has documented this combination effect to date. So, the current study is a trial to determine how agomelatine and vildagliptin, both individually and together, could alleviate the symptoms of diabetic nephropathy.

## 2. RESULTS

### 2.1. Biochemical profile

#### 2.1.1. Blood Glucose and Insulin Levels

At the end of the experiment, the FBGL was assessed to evaluate the efficacy of the used medications in decreasing the blood glucose levels. STZ administration caused a significant increase ( $p < 0.05$ ) in BGL in comparison to the control group, but vildagliptin, agomelatine, and also the combination of these drugs caused a significant decrease ( $p < 0.05$ ) in comparison to the diabetic group not receiving treatment (**Table 1**).

Regarding the serum insulin level, it was significantly reduced ( $p < 0.05$ ) in STZ-administered rats compared to the control group, while it was significantly increased in all treatment groups in comparison to the diabetic group not receiving treatment and better improvements in combinations of vildagliptin with agomelatine compared to that of vildagliptin treated group was detected at level of  $p < 0.05$  (**Table 1**).

#### 2.1.2. Blood Glucose Homeostasis

To study insulin resistance, the homeostasis model assessment of insulin resistance (HOMA-IR) calculation was assessed. Insulin resistance was significantly elevated ( $p < 0.05$ ) in STZ-induced diabetic rats when compared to the control group, a significant decrease ( $p < 0.05$ ) was observed in vildagliptin, agomelatine and combined vildagliptin and agomelatine-treated rats ( $p < 0.05$ ) in comparison to the STZ-induced diabetic rats and better improvements to that of vildagliptin treated group was detected at level of  $p < 0.05$  (**Table 1**).

The homeostasis model assessment of  $\beta$ -cell function (HOMA- $\beta$ ) was estimated to evaluate  $\beta$ -cells function. It was significantly decreased ( $p < 0.05$ ) in STZ-induced diabetic rats in comparison to the control group. While, HOMA  $\beta$ -cell showed insignificant increase in agomelatine-treated rats, a significant increase was observed in vildagliptin ( $p < 0.05$ ) and combined vildagliptin and agomelatine-treated rats ( $p < 0.05$ ) in comparison to the STZ-induced diabetic rats and better improvements to that of vildagliptin treated group was detected at level of  $p < 0.05$  (Table 1).

## 2.2. Total Antioxidant Capacity (TAC)

The serum TAC was significantly decreased ( $p < 0.05$ ) in STZ-induced diabetes in rats in serum TAC in diabetic rats in comparison to control rats. Treatment with vildagliptin, agomelatine, or the combination of these drugs significantly increased ( $p < 0.05$ ) the serum TAC compared to STZ-induced diabetic rats, and better improvements to that of vildagliptin treated group was detected at level of ( $p < 0.05$ ) (Table 1).

**Table 1.** Effect of administration of Vildagliptin/Agomelatine on the blood glucose, homeostasis, and serum total antioxidant capacity of the study.

Study variables	Cont.	D.M	D.M+ Vildag.	D.M+ Ago.	D.M+ (vildag.+Ago.)
Serum Fasting blood glucose (mg/dl)	79.91 $\pm$ 6.63	389.23 $\pm$ 59.05 <sup>a</sup>	180.51 $\pm$ 29.32 <sup>ab</sup>	229.07 $\pm$ 52.45 <sup>ab</sup>	172.34 $\pm$ 21.83 <sup>abc</sup>
Serum Insulin ( $\mu$ IU/ml)	5.74 $\pm$ 0.62	2.24 $\pm$ 0.28 <sup>a</sup>	3.49 $\pm$ 0.83 <sup>ab</sup>	3.22 $\pm$ 0.15 <sup>ab</sup>	5.17 $\pm$ 0.48 <sup>abc</sup>
HOMA-IR	1.02 $\pm$ 0.45	1.94 $\pm$ 0.65 <sup>a</sup>	1.30 $\pm$ 0.29 <sup>ab</sup>	1.54 $\pm$ 0.18 <sup>ab</sup>	1.68 $\pm$ 0.23 <sup>abc</sup>
HOMA- $\beta$ -cells	1.50 $\pm$ 0.55	0.12 $\pm$ 0.08 <sup>a</sup>	0.34 $\pm$ 0.11 <sup>ab</sup>	0.29 $\pm$ 0.14 <sup>ab</sup>	0.61 $\pm$ 0.17 <sup>abc</sup>
Serum total antioxidant capacity (TAC)(mM/dl)	284.50 $\pm$ 7.67	182.23 $\pm$ 10.18 <sup>a</sup>	235.55 $\pm$ 10.46 <sup>ab</sup>	244.23 $\pm$ 12.31 <sup>ab</sup>	279.12 $\pm$ 11.42 <sup>abc</sup>

Cont.: control, D.M: diabetes mellitus, Vildag.: Vildagliptin, Ago.: Agomelatine

Data are shown as mean  $\pm$  SD and showed:

<sup>a</sup>Significantly different compared to the control group at  $p < 0.05$ .

<sup>b</sup>Significantly different compared to the D.M exposed group at  $p < 0.05$ .

<sup>c</sup>Significantly different compared to the vildagliptin treated group at  $p < 0.05$

## 2.3. Kidney function tests

Compared to the control group rats, diabetic rats had lower levels of urea, uric acid, creatinine, and total antioxidant capacity. The diabetic rats displayed a significant increase ( $p < 0.05$ ) in the levels of urea, uric acid, and creatinine. Diabetic rats treated with vildagliptin (Vildag.), agomelatine (Ago.), or both (Vildag. + Ago.) presented a significant ( $p < 0.05$ ) enhancement in the levels of urea, uric acid and creatinine compared to the untreated diabetic rats. The statistical analysis showed that the STZ + Vildag. + Ago. rats had better improvements to that of Vildagliptin treated group was detected at level of ( $p < 0.05$ ) (Table 2).

**Table 2.** Effect of administration of vildagliptin/Agomelatine on the kidney functions.

Study variables	Serum urea (mg/dl)	Serum uric acid (mg/dl)	Serum creatinine (mg/dl)
Cont.	22.77 $\pm$ 0.78	2.22 $\pm$ 0.19	0.41 $\pm$ 0.31
D.M.	45.18 $\pm$ 1.34 <sup>a</sup>	7.06 $\pm$ 0.28 <sup>a</sup>	3.23 $\pm$ 0.61 <sup>a</sup>
D.M.+ Vildag.	26.25 $\pm$ 0.41 <sup>ab</sup>	2.98 $\pm$ 0.11 <sup>ab</sup>	1.67 $\pm$ 0.25 <sup>ab</sup>
D.M.+ Ago.	25.64 $\pm$ 0.22 <sup>ab</sup>	3.31 $\pm$ 0.14 <sup>ab</sup>	1.53 $\pm$ 0.19 <sup>ab</sup>
D.M.+ (Vildag. + Ago.)	23.24 $\pm$ 0.12 <sup>abc</sup>	2.53 $\pm$ 0.12 <sup>abc</sup>	1.32 $\pm$ 0.12 <sup>abc</sup>

Cont.: control, D.M: diabetes mellitus, Vildag.: Vildagliptin, Ago.: Agomelatine

Data are shown as mean  $\pm$  SD and showed:

<sup>a</sup>Significantly different compared to the control group at  $p < 0.05$ .

<sup>b</sup>Significantly different compared to the D.M exposed group at  $p < 0.05$ .

<sup>c</sup>Significantly different compared to the vildagliptin treated group at  $p < 0.05$

## 2.4. Renal oxidative status (MDA, GSH, SOD and NO)

MDA and NO levels were significantly higher in diabetic rats compared to the control group rats, which indicated that diabetes significantly ( $p < 0.05$ ) decreased oxidative stability. Vildagliptin, agomelatine, or both (Vildag. + Ago.) significantly decreased the levels of MDA and NO in diabetic rats after treatment, especially in the Vild. + Ago. treated diabetic rats compared to the untreated diabetic rats (Table 3).

While, the levels of the antioxidants GSH and SOD were found to be considerably lower ( $p < 0.05$ ) in rats of STZ-induced diabetes than that of the control group. The treatment of diabetic rats with Vild, Ago, and Vild + Ago. considerably increased the levels of the antioxidant GSH and SOD compared to the values of the group

of untreated diabetic rats ( $p < 0.05$ ). The statistical analysis results showed that Vild. +Ago. treatment exhibited superior improvements to that of vildagliptin treated group was detected at level of  $p < 0.05$  (Table 3).

**Table 3.** Effect of administration of Vildagliptin/Agomelatine on Renal oxidative status.

Study variables	MDA (nmol/mg)	NO(mg/g.tissue)	GSH(mg/g.tissue)	SOD (u/g. tissue)
Cont.	2.2± 1.05	15.47 ± 1.25	4.63± 0.37	275.75 ± 3.91
D.M.	12.94 ± 0.34 <sup>a</sup>	37.5 ± 1.81 <sup>a</sup>	2.03± 0.46 <sup>a</sup>	160.44 ± 4.63 <sup>a</sup>
D.M.+ Vildag.	6.80 ± 0.17 <sup>ab</sup>	20.5 ± 0.27 <sup>ab</sup>	3.9± 0.43 <sup>ab</sup>	215.66 ± 0.23 <sup>ab</sup>
D.M.+ Ago.	7.60 ± 0.71 <sup>ab</sup>	19.62 ± 1.93 <sup>ab</sup>	4.2± 0.83 <sup>ab</sup>	204.88 ± 6.24 <sup>ab</sup>
D.M.+ (Vildag. + Ago.)	5.21 ± 0.12 <sup>abc</sup>	17.34± 2.53 <sup>abc</sup>	4.64± 0.74 <sup>abc</sup>	232.87 ± 2.49 <sup>abc</sup>

Cont.: control, D.M: diabetes mellitus, Vildag.: Vildagliptin, Ago.: Agomelatine

Data are shown as mean ± SD and showed:

<sup>a</sup>Significantly different compared to the control group at  $p < 0.05$ .

<sup>b</sup>Significantly different compared to the D.M exposed group at  $p < 0.05$ .

<sup>c</sup>Significantly different compared to the vildagliptin treated group at  $p < 0.05$

## 2.5. Effects on Collagen & Bcl-2 levels

The percentage are of collagen density were significantly ( $p < 0.05$ ) increased in all diabetic groups in comparison to control rats. Treatment of diabetic rats with vildagliptin, agomelatine, or both considerably decreased the levels of collagen density compared to that of untreated diabetic rats. However, the kidney sections from the diabetic group showed a considerably decreased level of Bcl-2 expression based on the immunohistochemistry analysis in the current investigation than those from the control group ( $p < 0.05$ ), while vildagliptin or agomelatine treatment significantly increased this expression and the effect of combined treatment of both vildagliptin and agomelatine was found superior to that of vildagliptin treated group was detected at level of  $p < 0.05$  (Table 4).

**Table 4.** Assay of area percentage of Collagen & Bcl-2:

Study variables	Percentage are of Collagen density (%)	Bcl-2 immunexpression (area %)
Cont.	5.97 ± 1.32	23.46 ± 2.74
D.M.	12.21 ± 1.11 <sup>a</sup>	8.42±2.13 <sup>a</sup>
D.M.+ Vildag.	8.44 ± 0.82 <sup>ab</sup>	15.51±1.63 <sup>ab</sup>
D.M.+ Ago.	8.64 ± 1.04 <sup>ab</sup>	16.83±1.34 <sup>ab</sup>
D.M.+ (Vildag. + Ago.)	7.24 ± 1.31 <sup>abc</sup>	19.23±1.48 <sup>abc</sup>

Cont.: control, D.M: diabetes mellitus, Vildag.: Vildagliptin, Ago.: Agomelatine

Data are shown as mean ± SD and showed:

<sup>a</sup>Significantly different compared to the control group at  $p < 0.05$ .

<sup>b</sup>Significantly different compared to the D.M exposed group at  $p < 0.05$ .

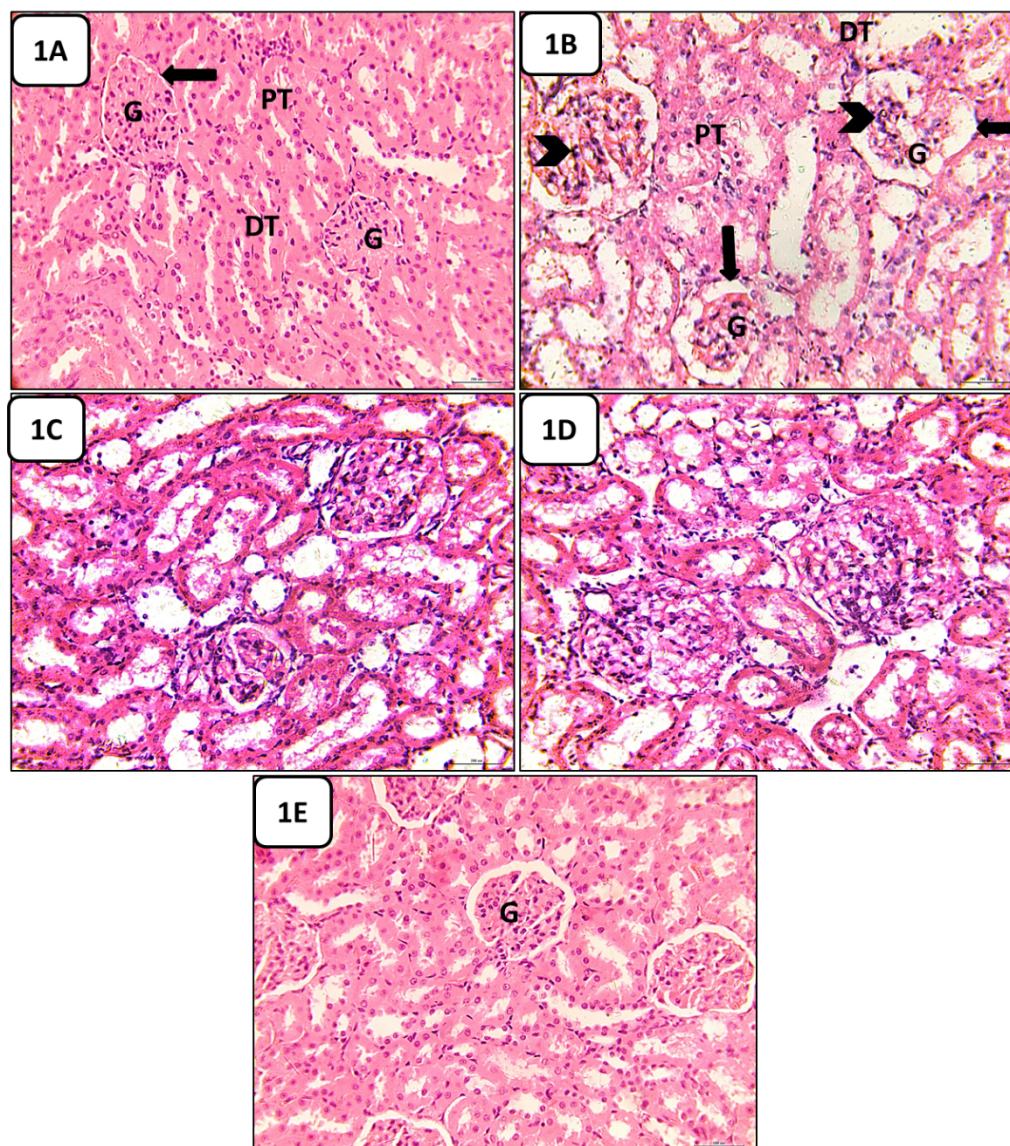
<sup>c</sup>Significantly different compared to the vildagliptin treated group at  $p < 0.05$

## 2.6. Histological Changes

### 2.6.1. Hematoxylin and Eosin-stained Sections Results

The cortex of the kidney of the control group revealed normal histological morphology of renal corpuscles, proximal and distal convoluted tubules. The kidney of diabetic rats revealed marked injury of glomeruli in the form of distended urinary space, thickened basement membrane of glomerular capillary, infiltration of inflammatory cells, widening, distortion of the renal tubules, as well as shranked glomeruli. While, Group III, IV&V: showed amelioration of those changes compared to the diabetic groups (Fig.1).



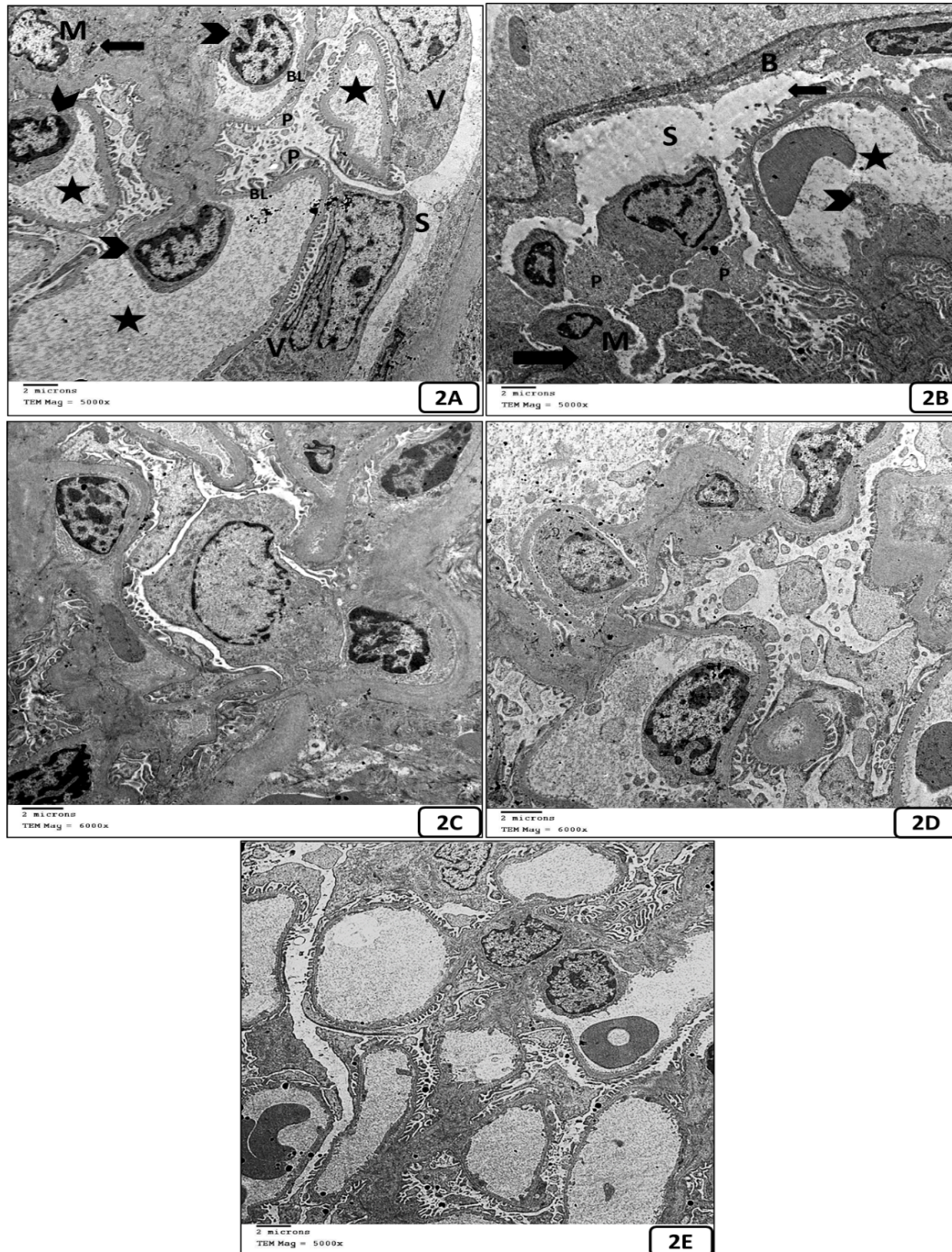


**Figure 1:** Photomicrographs of renal sections from control rats (A), diabetic rats (B), vildagliptin-treated rats (C), agomelatine-treated group (D) combination of vildagliptin and agomelatine treated group (E). The renal cortex of control group showed normal structure of the proximal tubules (PT), distal tubules (DT), and the glomerulus structures (G) with normal urinary space (arrow). The renal cortex of diabetic animals showed distorted different sized glomerulus (G) with enlarged urinary space (arrow), and inflammatory cells infiltration (arrow head), and distorted proximal and distal tubules. While the kidney tubules and renal glomeruli were noticeably restored in the cortex of diabetic rats' kidneys when treated with either vildagliptin or agomelatine with manifest improvement in the treated group with combination of both (Hx&E. stain x400) scale bar 200  $\mu$ m.

### 2.6.2. Ultrastructural changes

The electron micrograph of the kidneys from the control group reveals a typical ultrastructure (Fig. 2A). The glomeruli appear larger and dilated in diabetic rats, the Bowman's capsule is partially thickened, the podocytes are widened (Fig. 2B). The mentioned abnormalities were significantly normalized by oral treatment of vildagliptin and agomelatine, with superior action for combination of both (Fig. 2C, D and E).



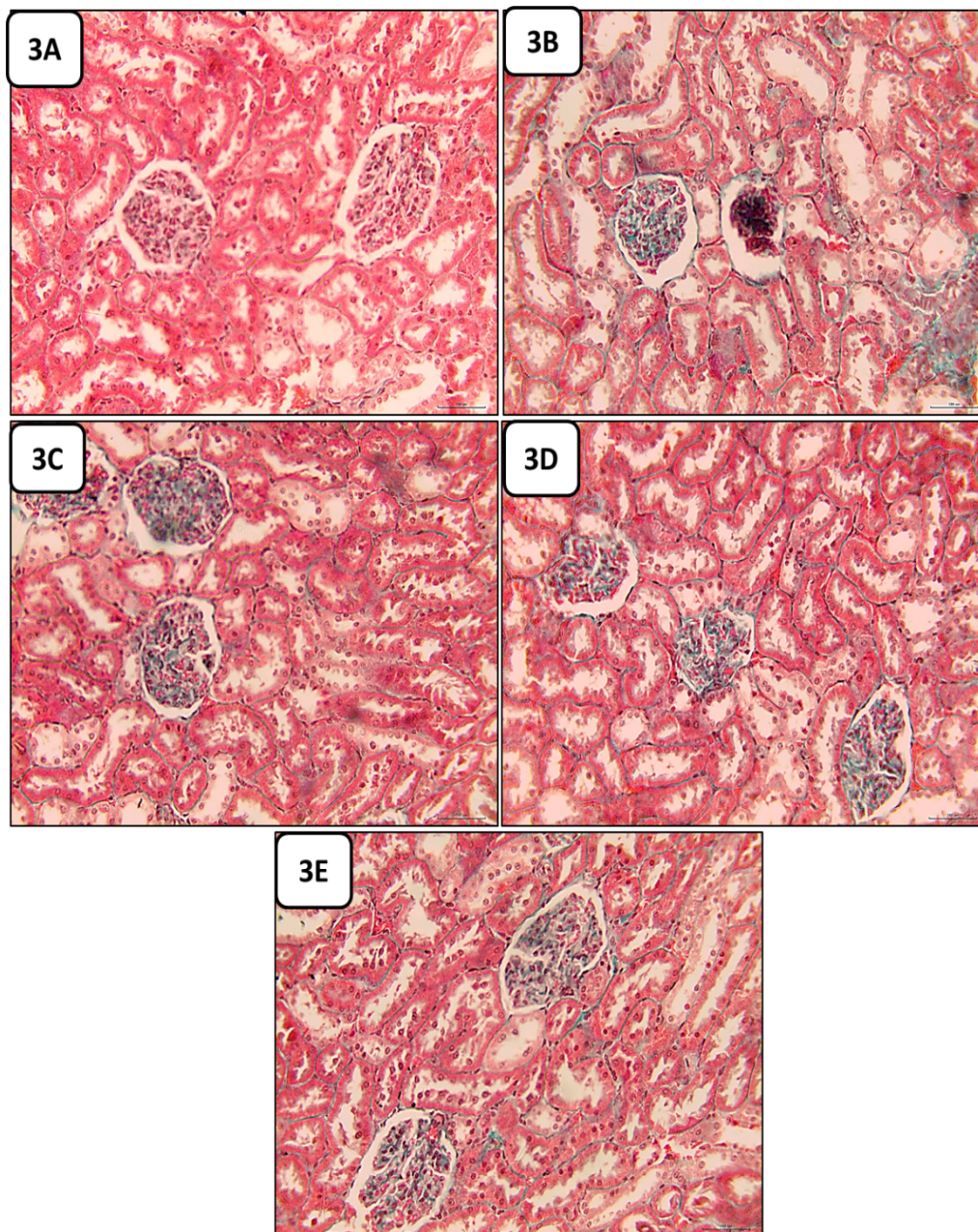


**Figure 2.** Electron photomicrographs of renal sections from the control (A), the diabetic group (B), vildagliptin-treated group (C), agomelatine-treated group (D) combination of vildagliptin and agomelatine treated group (E). Transmission electron micrograph of the control kidney showing preserved urinary space (S), small sized glomerular capillary loops (star), lined by fenestrated endothelial cells (head arrow) and the visceral epithelial cells (V) present at the urinary pole of the capillaries. The mesangium is found centrally among capillary loops containing mesangial cells (M) and Mesangial substance (arrow) support the capillary loops contacting the endothelial cells, the podocytes (P) resting on the basal lamina (BL) and surrounding the capillary loops. While, in the diabetic group the glomeruli appear larger, Bowman's capsule (B) is partially thickened and covered with granular matrix. Increased sized urinary space (S), Enlarged congested glomerular capillary loops (star) with degenerated endothelial cell (arrow head). The endothelium displays local abnormalities in profile and poor arrangement; some podocytes processes (P) appear broadened, while in the other treated diabetic kidneys, the pathological changes stated above are less present with superior improvement in combined treated group (Vildag. + Agom.) to that of single treatment (Vildag.) (lead citrate and uranyl acetate stain x 5000 & 6000) Scale bar = 2  $\mu$ m.



### 2.6.3. Detection of Intrarenal Collagen Fibers Deposition in the Studied Groups

Masson's trichrome-stained sections in the cortex of kidney of the control group revealed a normal deposition of collagen fibers around the kidney glomeruli and tubules, and STZ-induced diabetic group showed maximum deposition. While it showed in some degree normal deposition in vildagliptin-treated group, agomelatine-treated group, and the effect of combined administration of both was better than that of monotherapy (Fig. 3).

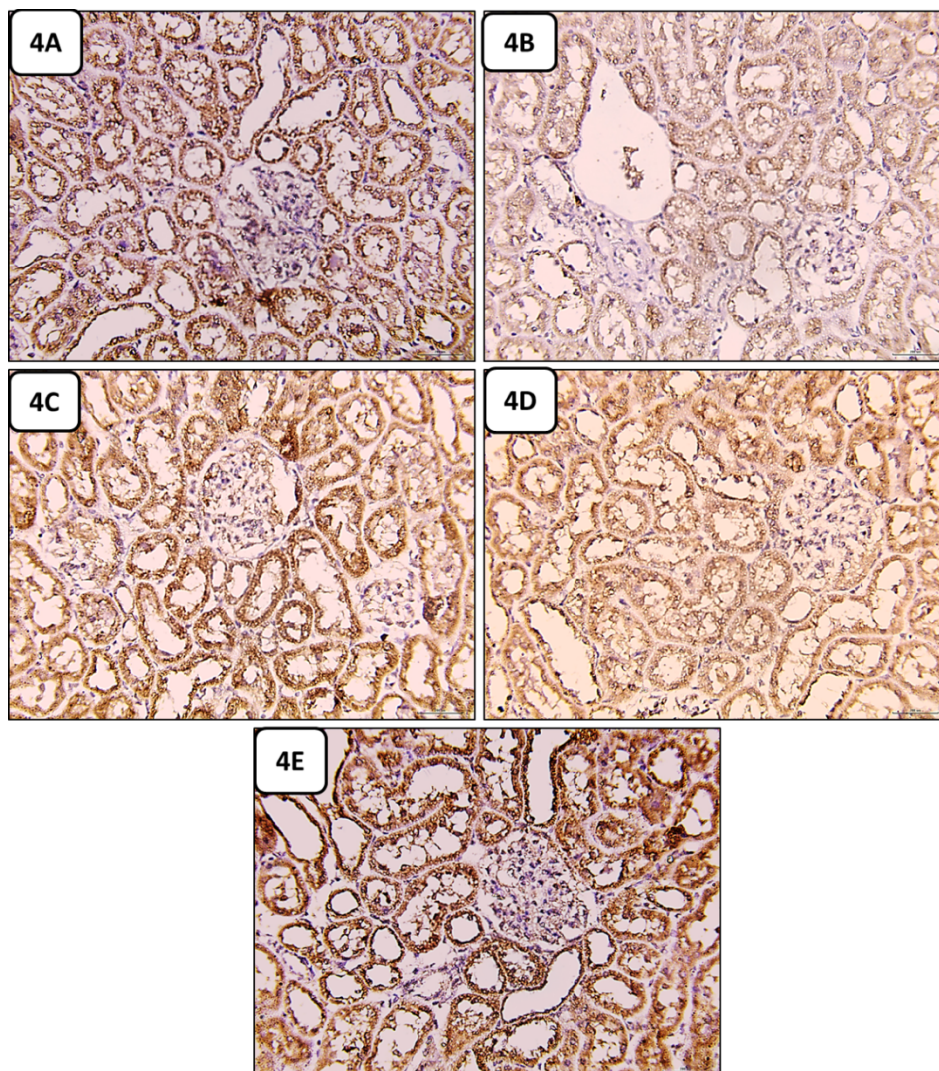


**Fig. 3:** Photomicrographs of Masson's trichrome-stained sections in the renal cortices depicted from (A) the control group showed minimum deposition (B) STZ-induced diabetic group showed maximum deposition. While, it showed in some degree normal deposition in (C) vildagliptin-treated group, (D) agomelatine-treated group, and (E) combination of vildagliptin and agomelatine treated group had superior to that of monotherapy with vildagliptin only (Masson trichrome stain. X400) (scale bar 200  $\mu$ m).



#### 2.6.4. Immunohistochemical Analysis of Bcl-2 in the Studied Groups:

The kidney sections from the untreated diabetic group showed a marked decrease in the level of Bcl-2 expression ( $p < 0.05$ ) compared to the control group, while vildagliptin or agomelatine treatment increased the levels of expression and the effect of combined treatment with both drugs was superior to that of monotherapy with vildagliptin only compared to the diabetic group ( $p < 0.05$ ) (Figure 4).



**Figure 4.** Photomicrographs of kidney cortex revealing the expression of Bcl-2 immunohistochemistry in different study groups. (A) the control group showed maximum expression (B) the STZ-induced diabetic group showed minimum expression, while it showed in some degree normal expression in (C) vildagliptin-treated group, (D) agomelatine-treated group, and (E) combination of vildagliptin and agomelatine treated group and the effect of combined administration of both was superior to that of monotherapy with vildagliptin only (Bcl-2 immunohistochemical staining. X400) (scale bar 200  $\mu$ m).

### 3. DISCUSSION

In the present study, we investigated the beneficial effects of agomelatine or vildagliptin on streptozotocin (STZ) induced diabetic rats and understanding the potential mechanisms underlying their nephroprotective effects. We used the model of STZ-induced diabetes in rats due to STZ's rapid elimination from the body, any changes shown in diabetic animals are thought to be a result of the diabetes itself rather than that of STZ [14].

Our findings showed that, after 4 weeks of diabetes induction by STZ, a remarkable increase in the level of blood glucose with a decrease in insulin levels compared to the control group. This was in accordance with the results of previous studies [13, 15] they detected a decrease in insulin levels after STZ induction that formed a model of diabetes very similar to type I DM. Free radicals may be a major cause in the development of STZ-induced diabetes by destroying pancreatic  $\beta$  cells [16]. Moreover that, several researches reported that

Streptozocin produced oxidative stress and exhaustion of the antioxidant systems in both blood and tissues [17, 18].

In this study, diabetes was found to impair the kidney function as noticed by increased levels of urea, uric acid, creatinine, and decreased total antioxidant capacity (TAC) in the diabetic rats compared to the control rats. Similar results were recently reported in the form of higher levels of serum urea and creatinine, indicating disturbance of kidney function of diabetic rats after four weeks of STZ injection [19].

The impairment in renal functions in diabetic rats included in this study was confirmed by histological examination of the kidney of diabetic rats which had observable injury and degenerative changes in the structure of kidney tissues were apparent. The kidney of diabetic rats revealed a clear visible damage to the glomerulus and renal tubules, including glomerular shrinkage, a thickened glomerular capillary basement membrane, evident inflammatory infiltration, tubular dilatation and distortion, and ambiguous tubular boundaries, an enlarged urinary space, as well as an enlarged, mesangial area and enlarged podocyte processes. Similarly, several earlier investigations on rats described comparable histological changes [20, 21].

Oxidative stress is a significant factor in the development of diabetic kidney disease (DKD), increased by an abundance of reactive oxygen species (ROS) and impaired the antioxidant systems [22]. In this study we found that the activities of GSH and SOD in the renal tissue and serum TAC, were significantly decreased in diabetic rats induced by STZ compared to that of control rats, indicating a deficiency in antioxidant systems. While the renal tissue levels of MDA and NO were increased compared to that of control rats indicating a manifest state of oxidative stress. The malondialdehyde (MDA) is the most prevalent sign of lipid peroxidation which is caused by an increase in free radicals [3]. Similar results regarding the oxidative and antioxidative defense system were observed in the kidneys of rat models of the experimentally produced STZ-induced type 2 diabetes [23].

Furthermore, oxidative stress may eventually cause renal fibrosis, which will impair kidney function [24]. In this study, induction of DM with STZ was associated with renal fibrosis, as noticed by increased detection of collagen density in Masson trichrome stained sections in diabetic rats in comparison to the control group. Similar results of collagen deposition were reported in diabetic kidneys of both human and animals [25, 26]. Also, In CKD patients, fibrosis is a pathogenic reaction to injury, regardless of the underlying cause [27].

Moreover, according to several studies, hyperglycemia-induced oxidative stress can lead to apoptosis, kidney damage, and ultimately organ failure [28, 29]. Our study revealed that immunohistochemical assay of the anti-apoptotic protein Bcl2's expressions in the kidneys of diabetic rats was significantly decreased in comparison to the control group. This was in agreement to a recent study revealed a decrease in the anti-apoptotic protein Bcl2's concentrations in the renal tissue of diabetic rats [19, 30].

Therefore, controlling blood glucose and insulin levels in diabetes may assist to delay or avoid the onset of diabetic complications including nephropathy. Also, suppressing the increased oxidative stress is one of the most crucial approaches to avoid programmed cell death in diabetic nephropathy.

In the current study, treatment of diabetic rats with vildagliptin (antidiabetic) significantly improved the glycemic control, renal function, reduced histopathological changes, and reduced the deposition of interstitial renal collagen fibers. This was in harmony with a previous research on vildagliptin which was found to improve the reduction in insulin levels in STZ-induced diabetic rats [31]. The elevated insulin levels seen here following vildagliptin treatment, was explained by improvement in islet histology in non-obese diabetic (NOD) mice whose beta cells were damaged by a spontaneous autoimmune reaction that resulted in a condition similar to type 1 diabetes following treatment with vildagliptin {glucagon-like peptide-1 (GLP-1)} these improvements occurred due to elevated levels of GLP-1 as a result of DPP-4 inhibition of vildagliptin [32].

Also, in our study, vildagliptin administration to diabetic rats was found to improve the kidney function including decreased serum levels of creatinine, urea, and uric acid compared to diabetic rats. This is constant with both in vitro and in vivo studies [33, 34]. The possible mechanism could be the activation of the cyclic adenosine monophosphate-protein kinase A (cAMP-PKA) by the DPP-4 inhibitors like vildagliptin, which results in an increase in cAMP and a subsequent decrease in levels of nicotinamide adenine dinucleotide phosphate (NAD(P)H) oxidase, this may protect the kidneys from hyperglycemia-induced by oxidative stress according to preclinical studies [35, 36].

Similar to vildagliptin treatment, we used agomelatine administration to diabetic rats which resulted in lowering blood glucose levels. These findings harmonize with previous studies on either agomelatine [13] or melatonin [10] administration to diabetic rats' were found to decrease blood glucose levels to normal glucose levels. This could be due to an increase in total antioxidant capacity following administration of



agomelatine & its efficacy in reducing the production of proinflammatory mediators and the expression of their mRNAs, including IL-1, in macrophages which participates in the pathogenesis of T2DM [13].

Moreover, in this study, we found that agomelatine treatment of the diabetic rats resulted in improving of kidney function compared to the diabetic rats. In agreement to our results, melatonin was found to have renoprotective effects in diabetic rats [10]. This could be due to agomelatine and melatonin antioxidative property as, antioxidants play a diversity of physiological roles, including scavenging and reducing the harmful effects of free radicals and enhancing the body's defense mechanisms by inducing antioxidant enzymes and proteins that are involved in antioxidant pathways [37].

In the present study, the improvement in kidney function was approved by histological study in the form of restoration of the previous changes caused by diabetes. This was in agreement to several studies have shown that either administration of melatonin or vildagliptin can decrease the blood glucose levels and ameliorate the pathological damage caused by high glucose levels through their antioxidative activities [38, 39].

In the current study, vildagliptin had a positive effect on oxidative stress in the form of increase in the activities of glutathione (GSH) and superoxide dismutase (SOD), decrease in the MDA and NO levels in the renal tissue. This could be due to decreasing NADPH oxidase expression and ROS production [40].

Moreover, our findings showed positive effects of agomelatine on antioxidant capacity as agomelatine treatment has been shown to increase the activities of glutathione (GSH) and superoxide dismutase (SOD), decrease in the MDA and NO levels in the renal tissue. This in agreement to earlier research demonstrating the antioxidant characteristics of various antidepressants, such as agomelatine [41]. Therefore, agomelatine treatment can protect against renal damage induced by oxidative stress due to its antioxidant properties.

In our study, treatment with combination of both vildagliptin and agomelatine improved the glycemic control, renal function, reduced histopathological changes, and reduced the deposition of interstitial renal collagen fibers compared to the diabetic group. This could be due to the synergistic effect of their antioxidative, antiapoptotic, antifibrotic properties and improvements in glucose metabolism.

Finally, the use of either vildagliptin or agomelatine or both in the treatment of diabetes could alleviate diabetic complications including nephropathy due to their antioxidative antiapoptotic, antifibrotic properties. Our study has one limitation that we could have assessed the blood electrolytes which would have contributed in causing nephrotoxicity

#### 4. CONCLUSION

Administration of adjusted-dose of STZ in a rat model exhibits symptoms similar to T2DM. This induction led to nephropathic changes in rat's kidney. Combination of agomelatine and vildagliptin could ameliorate nephropathy in diabetic rats induced by streptozotocin through inhibition of oxidative stress.

#### 5. MATERIALS AND METHODS

##### 5.1. Ethical clearance

The medical ethical committee at the Damietta faculty of medicine, Al-Azhar university, Egypt, gave its approval before the study was launched [DFM-IRB 00012367 -22-010-007].

##### 5.2. Chemicals

Agomelatine (Agovald® 25 mg tablet), was supplied by Mash Premiere, Egypt. Tablets were dissolved in 1% hydroxyethyl cellulose (HEC) before administration by oral lavage immediately at the indicated dose. Vildagliptin (Galvus® 50 Mg tablet) was kindly provided by Novartis Pharma Company, Cairo, Egypt. Streptozocin (STZ) were provided from Sigma-Aldrich Chemical Co., St Louis, MO, USA. The dose, time of administration and the duration of treatment of agomelatine, vildagliptin and streptozotocin were guided by previous publications respectively [7, 42, 43].

##### 5.3. Animals

Fifty male Albino rats 6-8 weeks of age (120-150 g) were obtained from Serum and Vaccine Institute at the Agricultural Research Center, Cairo, Egypt.

## 5.4. Induction of Diabetes mellitus

For induction of diabetes, Streptozocin (STZ) was injected intraperitoneal at a dose of 60 mg/kg BW in fasted rats for 12 hours followed by a 5% sucrose solution mixed in 0.01 M sodium citrate buffer, pH 4.5 [43].

## 5.5. Experimental design

Every day, drinking water was replaced, and every other day, cages were cleaned. Rats were housed in rooms that were 21 °C, 55–60% humidity outside, and alternated between 12 hours of light and 12 hours of darkness with free access to water and normal pellet feed throughout the investigation.

Five groups of rats (n = 10) were included: group I (control group) given normal saline solution by oral gavage and four other groups were injected with STZ for the induction of diabetes. The blood glucose level (BGL) was measured from the rat's tail vein 1 week after STZ injection to confirm induction of diabetes, and diabetes was considered in rats with a BGL of 250 mg/dl or more, then they were classified into: Group II (diabetic group): given normal saline (5 mL/kg b.w./day) by oral gavage for four weeks. Group III: diabetic rats treated with vildagliptin daily at a dose level of 10 mg/kg b.w./day by oral gavage for four weeks, Group IV: diabetic rats treated with agomelatine daily at a dose of 20 mg/kg b.w./day by oral gavage for four weeks, Group V: diabetic rats treated with both vildagliptin and agomelatine daily at the former doses (vildagliptin 10 mg/kg b.w./day, agomelatine 20 mg/kg b.w./day) via oral gavage for 4 weeks.

## 5.6. Biochemical analyses

Blood samples from the retro-orbital plexus were obtained at the end of the study, and serum was separated by centrifugation at 1200 g for 15 min. For additional biochemical analyses, serum was then collected and stored at 20°C. According to the manufacturer's instructions, fasting blood glucose level (FBGL) was measured two times (after diabetes induction and at the end of the therapy by using enzymatic kits (Human Gesellschaft für Diagnostica GmbH, Germany), and serum insulin level was measured once (after induction of diabetes) by using ELISA kits (DRG, USA, Cat. No: DEIA1897).

Based on the following formula, estimation of the HOMA model for investigating insulin resistance (HOMA-IR) and  $\beta$ -cells functions (HOMA  $\beta$ -cells):  $HOMA-IR = \text{fasting serum glucose (mg/dl)} \times \text{fasting serum insulin } (\mu\text{U/ml}) / 405$ .  $HOMA-\beta \text{ cell function} = 20 \times \text{fasting serum insulin } (\mu\text{U/ml}) / \text{fasting serum glucose (mg/dl)} - 3.5$  [44]. Also, following the manufacturer's instructions, the total antioxidant capacity (TAC) was calculated using the Bio-diagnostic kit method.

## 5.7. Investigations of Kidney Functions

Using spectrum diagnostic kits, Egypt, the serum urea, uric acid, and creatinine levels were measured. Following the manufacturers' directions, all assays were performed.

## 5.8. Determination of Oxidative Stress and Anti-Oxidant Defense Parameters

### 5.8.1. Preparation of Tissue Homogenates

A section of the kidney specimen was removed, washed with ice-cold water, and then homogenized at 4 °C in 0.1 M Tris-HCl buffer (pH 7.4) using a Teflon homogenizer. The debris was removed from the homogenate by centrifuging it at 13,000 g, and the supernatant was then utilized to calculate the protein content of the tissue homogenate [45].

### 5.8.2. Investigations of Oxidative Stress and Anti-Oxidant Defense Parameters

The manufacturer's guidelines were followed in evaluation of Superoxide dismutase (SOD), Glutathione (GSH), Nitric Oxide (NO), and Malondialdehyde (MDA) in the kidneys using commercially available kits (Biodiagnostic Co., Giza, Egypt).

## 5.9. Assessment of Histological Changes

### 5.9.1. Light Microscopic Study

The rats were sacrificed by cervical decapitation, for at least 24 hours, fixation of kidney specimen in 10% formalin. The obtained renal tissues were prepared, sectioned at a thickness of 5 m, dehydrated, cleaned, and then mounted and stained with Hx.&E. to detect the histological changes [46], Masson's Trichrome to evaluate the incidence of fibrosis [47] and immune stain for the anti-apoptotic factor Bcl-2 [30] in renal tissue. Light microscopy (Raywild, Germany) was used to examine the produced slides. A digital camera with an

image-analyzing system (optimus v12) was used to capture images and estimate the % area density of collagen fibres and Bcl2 at a magnification of 40X.

### 5.9.2. Transmission Electron Microscopic Study

A part of fresh kidney (about 1 mm<sup>3</sup>) was excised from the rats of each group and fixed in 3% glutaraldehyde in sodium phosphate buffer (0.2 M, pH 7.4) for 3 h at 4°C. Tissue samples were washed with the same buffer, post-fixed in 1% osmium tetroxide and sodium phosphate buffer (0.2 M, pH 7.4) for 1 h at 4 °C. rewashing of samples with the same buffer for 3 h at 4°C, dehydrated with grades of alcohol and embedded in Araldite. Thin sections were cut with a diamond knife of Ultramicrotome (LKBUM4) using, mounted on a copper grid and stained with lead citrate and uranyl acetate. The grids were examined under the transmission electron microscope (Philips EM201C).

### 6. Statistics

The statistical program SPSS for Windows (Version 21.0; SPSS Inc., Chicago, IL, USA) was used to analyze the data. The two-tailed Student's t-test and one-way ANOVA were used, followed by Duncan's post hoc test for multiple group comparison. The mean SE is used to represent data. Statistical significance was accepted at level of p<0.05.

**Author contributions:** in this study author contributions were equal according to each specialty in: Concept; Design; Supervision; Resource; Materials; Data Collection &/or Processing; Analysis &/or Interpretation; Literature Search; Writing; and Critical Reviews.

**Conflict of interest statement:** The authors declared no conflict of interest and no financial or personal relationships that may be perceived as influencing our work

### REFERENCES

- [1] Islam F, Khadija JF, Islam R, Shohag S, Mitra S, Alghamdi S, Babalghith A, Theyab A, Rahman M, Akter A, Al Mamun A, Alhumaydhi F, Bin Emran T. Investigating polyphenol nanoformulations for therapeutic targets against diabetes mellitus. Evidence-Based Complementary and Alternative Medicine. 2022;2022. <https://doi.org/10.1155/2022/5649156>
- [2] Sun X, Yang Y, Sun X, Meng H, Hao W, Yin J, Ma F, Guo X, Du L, Sun L, Wu H. Krill Oil Turns Off TGF-β1 Profibrotic Signaling in the Prevention of Diabetic Nephropathy. Journal of Agricultural and Food Chemistry. 2022;70(32):9865-76. <https://doi.org/10.1021/acs.jafc.2c02850>
- [3] Luo Q, Cai Y, Zhao Q, Jiang Y, Tian L, Liu Y, Liu W. Renal Protective Effects of Melatonin in Animal Models of Diabetes Mellitus-Related Kidney Damage: A Systematic Review and Meta-Analysis. Journal of Diabetes Research. 2022;2022. <https://doi.org/10.1155/2022/3770417>
- [4] Keelo R, Elbe H, Bicer Y, Yigitturk G, Koca O, Karayakali M, Acar D, Altinoz E. Treatment with crocin suppresses diabetic nephropathy progression via modulating TGF-β1 and oxidative stress in an experimental model of pinealectomized diabetic rats. Chemico-Biological Interactions. 2022;351:109733. <https://doi.org/10.1016/j.cbi.2021.109733>
- [5] Horiba Y, Ishizawa K, Takasaki K, Miura J, Babazono T. Effect of depression on progression to end-stage renal disease or pre-end-stage renal disease death in advanced diabetic nephropathy: A prospective cohort study of the Diabetes Study from the Center of Tokyo Women's Medical University. Journal of Diabetes Investigation. 2022;13(1):94-101. <https://doi.org/10.1111/jdi.13620>
- [6] Sherif I, Alshaalan A, Al-Shaalan N. Renoprotective effect of vildagliptin following hepatic ischemia/reperfusion injury. Renal Failure. 2020;42(1):208-15. <https://doi.org/10.1080/0886022X.2020.1729189>
- [7] Wahba N, Abdel-Ghany R, Ghareib S, Abdel-Aal M, Alsemeh A, Sabry D. Vitamin D3 potentiates the nephroprotective effects of vildagliptin-metformin combination in a rat model of metabolic syndrome. Fundamental & Clinical Pharmacology. 2022;36(2):306-23. <https://doi.org/10.1111/fcp.12721>
- [8] Thomas H, Ford Versypt A. Pathophysiology of mesangial expansion in diabetic nephropathy: mesangial structure, glomerular biomechanics, and biochemical signaling and regulation. Journal of Biological Engineering. 2022;16(1):1-13. <https://doi.org/10.1186/s13036-022-00299-4>
- [9] Elbe H, Vardi N, Esrefoglu M, Ates B, Yologlu S, Taskapan C. Amelioration of streptozotocin-induced diabetic nephropathy by melatonin, quercetin, and resveratrol in rats. Human & experimental toxicology. 2015;34(1):100-13. <https://doi.org/10.1177/0960327114531995>

- [10] Alqasim A, Eldin E, Hammadi S, Esheba G. Comparing the renoprotective effects of the antioxidants melatonin, vitamin D and vitamin E in diabetic rats. *Journal of Taibah University Medical Sciences*. 2020;15(5):351-7. <https://doi.org/10.1016/j.jtumed.2020.05.007>
- [11] Chenaf C, Chapuy E, Libert F, Marchand F, Courteix C, Bertrand M, Gabriel C; Mocaër E, Eschalier A, Authier N. Agomelatine: a new opportunity to reduce neuropathic pain—preclinical evidence. *Pain*. 2016;158(1):149-60. <https://doi.org/10.1097/j.pain.0000000000000738>
- [12] Castanho A, Bothorel B, Seguin L, Mocaër E, Pévet P. Like melatonin, agomelatine (S20098) increases the amplitude of oscillations of two clock outputs: melatonin and temperature rhythms. *Chronobiology International*. 2014;31(3):371-81. <https://doi.org/10.3109/07420528.2013.860457>
- [13] Ozcan M, Canpolat S, Bulmus O, Ulker N, Tektemur A, Tekin S, Ozcan S, Serhatlioglu I, Kacar E, Ayar A, Kelestimur H. Agomelatine pretreatment prevents development of hyperglycemia and hypoinsulinemia in streptozotocin-induced diabetes in mice. *Fundamental & clinical pharmacology*. 2019;33(2):170-80. <https://doi.org/10.1111/fcp.12413>
- [14] Hirano S, Miyata S, Onodera K, Kamei J. Effects of histamine H1 receptor antagonists on depressive-like behavior in diabetic mice. *Pharmacology Biochemistry and Behavior*. 2006;83(2):214-20. <https://doi.org/10.1016/j.pbb.2006.02.001>
- [15] Haligur M, Topsakal S, Ozmen O. Early degenerative effects of diabetes mellitus on pancreas, liver, and kidney in rats: an immunohistochemical study. *Experimental diabetes research*. 2012;2012. <https://doi.org/10.1155/2012/120645>
- [16] Al-Qulaly M, Okasha MA, Hassan MG. Effect of Ginger and Cinnamon on Induced Diabetes Mellitus in Adult Male Albino Rats. *Bulletin of Egyptian Society for Physiological Sciences*. 2021;41(3):373-88. <https://doi.org/10.21608/BESPS.2020.45577.1078>
- [17] Anwar MM, Meki A-RM. Oxidative stress in streptozotocin-induced diabetic rats: effects of garlic oil and melatonin. *Comparative Biochemistry and Physiology Part A: Molecular & Integrative Physiology*. 2003;135(4):539-47. [https://doi.org/10.1016/s1095-6433\(03\)00114-4](https://doi.org/10.1016/s1095-6433(03)00114-4)
- [18] Gul M, Laaksonen DE, Atalay M, Vider L, Hänninen O. Effects of endurance training on tissue glutathione homeostasis and lipid peroxidation in streptozotocin-induced diabetic rats. *Scandinavian journal of medicine & science in sports*. 2002;12(3):163-70. <https://doi.org/10.1034/j.1600-0838.2002.120307.x>
- [19] Abd Wahab N, Giribabu N, Kilari EK, Salleh N. Abietic acid ameliorates nephropathy progression via mitigating renal oxidative stress, inflammation, fibrosis and apoptosis in high fat diet and low dose streptozotocin-induced diabetic rats. *Phytomedicine*. 2022;107:154464. <https://doi.org/10.1016/j.phymed.2022.154464>
- [20] Tunçdemir M, Ozturk M. The effects of ACE inhibitor and angiotensin receptor blocker on clusterin and apoptosis in the kidney tissue of streptozotocin-diabetic rats. *Journal of molecular histology*. 2008;39:605-16. <https://doi.org/10.1007/s10735-008-9201-2>
- [21] Vardı N, Iraz M, Gül M, Öztürk F, Uçar M, Otlı A. Improving effects of aminoguanidine on the histologic alterations in rat kidneys in diabetes. *Turkiye Klinikleri J Med Sci*. 2006;26:599-606.
- [22] Jha J, Banal C, Chow B, Cooper M, Jandeleit-Dahm K. Diabetes and kidney disease: role of oxidative stress. *Antioxidants & redox signaling*. 2016;25(12):657-84. <https://doi.org/10.1089/ars.2016.6664>
- [23] Sankaranarayanan C, Kalaivani K. Isopulegol mitigates hyperglycemia mediated oxidative and endoplasmic reticulum stress in HFD/STZ induced diabetic rats. *Archives of Medical Research*. 2020;51(3):204-14. <https://doi.org/10.1016/j.arcmed.2020.02.001>
- [24] Li S, Lin Q, Shao X, Mou S, Gu L, Wang L, Zhang Z, Shen J, Zhou Y, Qi C, Jin H, Pang H, Ni Z. NLRP3 inflammasome inhibition attenuates cisplatin-induced renal fibrosis by decreasing oxidative stress and inflammation. *Experimental cell research*. 2019;383(1):111488. <https://doi.org/10.1016/j.yexcr.2019.07.001>
- [25] Alsaad K, Edrees B, Rahim KA, Alanazi A, Ahmad M, Aloudah N. Collagenofibrotic (Collagen Type III) glomerulopathy in association with diabetic nephropathy. *Saudi Journal of Kidney Diseases and Transplantation*. 2017;28(4):898.
- [26] Wang L, Liu J, Ning W, Yuan Q, Zhang F, Peng Z, Lu M, Luo R, Fu Z, Hu G, Wang Z, Tao L. Fluorofenidone attenuates diabetic nephropathy and kidney fibrosis in db/db mice. *Pharmacology*. 2011;88(1-2):88-99. <https://doi.org/10.1159/000329419>
- [27] Humphreys B. Mechanisms of renal fibrosis. *Annual review of physiology*. 2018;80:309-26. <https://doi.org/10.1146/annurev-physiol-022516-034227>



- [28] Sapian S, Budin S, Taib I, Mariappan V, Zainalabidin S, Chin K. Role of polyphenol in regulating oxidative stress, inflammation, fibrosis, and apoptosis in diabetic nephropathy. *Endocrine, Metabolic & Immune Disorders-Drug Targets (Formerly Current Drug Targets-Immune, Endocrine & Metabolic Disorders)*. 2022;22(5):453-70. <https://doi.org/10.2174/187153032166621119144309>
- [29] Singh A, Kukreti R, Saso L, Kukreti S. Mechanistic insight into oxidative stress-triggered signaling pathways and type 2 diabetes. *Molecules*. 2022;27(3):950. <https://doi.org/10.3390/molecules27030950>
- [30] Mohany M, Ahmed M, Al-Rejaie S. The Role of NF- $\kappa$ B and Bax/Bcl-2/Caspase-3 Signaling Pathways in the Protective Effects of Sacubitril/Valsartan (Entresto) against HFD/STZ-Induced Diabetic Kidney Disease. *Biomedicines*. 2022;10(11):2863. <https://doi.org/10.3390/biomedicines10112863>
- [31] Pintana H, Apaijai N, Chattipakorn N, Chattipakorn SC. DPP-4 inhibitors improve cognition and brain mitochondrial function of insulin-resistant rats. *J Endocrinol*. 2013;218(1):1-11. <https://doi.org/10.1530/IOE-12-0521>
- [32] Li Y, Hansotia T, Yusta B, Ris F, Halban PA, Drucker DJ. Glucagon-like peptide-1 receptor signaling modulates  $\beta$  cell apoptosis. *Journal of Biological Chemistry*. 2003;278(1):471-8. <https://doi.org/10.1074/jbc.M209423200>
- [33] Shimodaira M, Niwa T, Nakajima K, Kobayashi M. Beneficial effects of vildagliptin on metabolic parameters in patients with type 2 diabetes. *Endocrine, Metabolic & Immune Disorders-Drug Targets (Formerly Current Drug Targets-Immune, Endocrine & Metabolic Disorders)*. 2015;15(3):223-8. <https://doi.org/10.1074/jbc.M209423200>
- [34] Marques A, Cunha-Santos J, Leal H, Sousa-Ferreira L, de Almeida L, Cavadas C, Rosmaninho-Salgado J. Dipeptidyl peptidase IV (DPP-IV) inhibition prevents fibrosis in adipose tissue of obese mice. *Biochimica et Biophysica Acta (BBA)-General Subjects*. 2018;1862(3):403-13. <https://doi.org/10.1016/j.bbagen.2017.11.012>
- [35] Greco E, Russo G, Giandalia A, Viazzi F, Pontremoli R, De Cosmo S. GLP-1 receptor agonists and kidney protection. *Medicina*. 2019;55(6):233. <https://doi.org/10.3390/medicina55060233>
- [36] Fujita H, Morii T, Fujishima H, Sato T, Shimizu T, Hosoba M, Tsukiyama K, Narita T, Takahashi T, Drucker D, Seino Y, Yamada Y. The protective roles of GLP-1R signaling in diabetic nephropathy: possible mechanism and therapeutic potential. *Kidney international*. 2014;85(3):579-89. <https://doi.org/10.1038/ki.2013.427>
- [37] Dennis JM, Witting PK. Protective role for antioxidants in acute kidney disease. *Nutrients*. 2017;9(7):718. <https://doi.org/10.3390/nu9070718>
- [38] Guo C, He J, Deng X, Wang D, Yuan G. Potential therapeutic value of melatonin in diabetic nephropathy: improvement beyond anti-oxidative stress. *Archives of Physiology and Biochemistry*. 2021:1-12. <https://doi.org/10.1080/13813455.2021.1933539>
- [39] Aghahoseini F, Alihemmati A, Hosseini L, Badalzadeh R. Vildagliptin ameliorates renal injury in type 2 diabetic rats by suppressing oxidative stress. *Journal of Diabetes & Metabolic Disorders*. 2020;19:701-7. <https://doi.org/10.1007/s40200-020-00548-7>
- [40] Rodríguez C, Contreras C, Sáenz-Medina J, Muñoz M, Corbacho C, Carballido J, García-Sacristán A, Hernandez M, López M, Rivera L, Prieto D. Activation of the AMP-related kinase (AMPK) induces renal vasodilatation and downregulates Nox-derived reactive oxygen species (ROS) generation. *Redox Biology*. 2020;34:101575. <https://doi.org/10.1016/j.redox.2020.101575>
- [41] Yigitturk G, Acara A, Erbas O, Oltulu F, Yavasoglu N, Uysal A, Yavasoglu A. The antioxidant role of agomelatine and gallic acid on oxidative stress in STZ induced type I diabetic rat testes. *Biomedicine & pharmacotherapy*. 2017;87:240-6. <https://doi.org/10.1016/j.biopha.2016.12.102>
- [42] Fathi D, Abulsoud AI, Saad M, Nassar N, Maksimos M, Rizk S, Senousy M. Agomelatine attenuates alcohol craving and withdrawal symptoms by modulating the Notch1 signaling pathway in rats. *Life Sciences*. 2021;284:119904. <https://doi.org/10.1016/j.lfs.2021.119904>
- [43] AlMohaimeed H, Mohammedsahleh Z, Batawi A, Balgoon M, Ramadan O, Baz H, Al Jaouni S, Ayuob N. Synergistic Anti-inflammatory and Neuroprotective Effects of Cinnamomum cassia and Zingiber officinale Alleviate Diabetes-Induced Hippocampal Changes in Male Albino Rats: Structural and Molecular Evidence. *Frontiers in Cell and Developmental Biology*. 2021;9. <https://doi.org/10.3389/fcell.2021.727049>
- [44] Matthews D, Hosker J, Rudenski A, Naylor B, Treacher D, Turner R. Homeostasis model assessment: insulin resistance and  $\beta$ -cell function from fasting plasma glucose and insulin concentrations in man. *Diabetologia*. 1985;28(7):412-9. <https://doi.org/10.1007/BF00280883>
- [45] Huculeci R, Dinu D, Staicu A, Munteanu M, Costache M, Dinischiotu A. Malathion-induced alteration of the antioxidant defence system in kidney, gill, and intestine of *Carassius auratus gibelio*. 2009;24(6):523-30. <https://doi.org/10.1002/tox.20454>



- [46] Bancroft J, Layton C. Theory & practice of histological techniques, 7th ed: Churchill Livingstone of Elsevier, Philadelphia. 2013:172-214.
- [47] Magalhães P, Pejchinovski M, Markoska K, Banasik M, Klinger M, Švec-Billá D, Rychlík I, Rroji M, Restivo A, Capasso G, Bob F, Schiller A, Ortiz A, Perez-Gomez M, Cannata P, Sanchez-Niño M, Naumovic R, Brkovic V, Polenakovic M, Mullen W, Vlahou A, Zürbig P, Pape L, Ferrario F, Denis C, Spasovski G, Mischak H & Schanstra J. Association of kidney fibrosis with urinary peptides: a path towards non-invasive liquid biopsies? Scientific Reports. 2017;7(1):1-8. <https://doi.org/10.1038/s41598-017-17083-w>