

# Sub-chronic Toxicity: Biochemical and Histopathological Profiling of Cincalok Oil in Wistar Rats

Hadi KURNIAWAN<sup>1</sup>, Inarah FAJRIATY<sup>1</sup>, Siti Nani NURBAETI<sup>1</sup>, Fajar NUGRAHA<sup>1</sup>,  
Fortunata Saesarria DEISBERANDA<sup>1</sup>, Dian WHIDYASTUTI<sup>1</sup>

<sup>1</sup> Department of Pharmacy, Medical Faculty, Universitas Tanjungpura, Pontianak, Indonesia.

\* Corresponding Author. E-mail: hadi.kurniawan@pharm.untan.ac.id (H.K.); Tel. +62-8-96-9361-4519.

Received: 11 January 2023 / Revised: 05 April 2023 / Accepted: 04 May 2023

**ABSTRACT:** Cincalok is a fermented shrimp from West Kalimantan, Indonesia, which has many beneficial compounds such as omega-3 and astaxanthin. The LD<sub>50</sub> of the cincalok oil was more than 5000 mg/ Kg BW (practically non-toxic), so there is an opportunity that cincalok can develop into a supplement. However, single and repeated doses may have different toxic potential. This study aimed to observe the sub-chronic toxicity of cincalok oil in Wistar strain rats (*Rattus norvegicus* L.) after 28 days of repeat doses in oral administration based on OECD 407 test guidelines. Thirty of the male and female Wistar strain rats were divided into six groups respectively that consisted of one control group of Virgin Coconut Oil (VCO) administration, three dosing groups of cincalok oil administration with dose variation of 100, 400, and 1000 mg/Kg BW, and two satellite groups of 1000 mg/Kg BW dose of cincalok oil administration and VCO control administration. The biochemistry and histopathological investigation was performed. The results showed the biochemical profiles of cincalok oil has no effect on LDL, urea, creatinine, serum glutamate oxaloacetate transaminase, and serum glutamate pyruvate transaminase blood profiles. While on total cholesterol, triglycerides, and HDL profiles, it has reversible effect. Histopathological investigation showed minimal fat degeneration with little congestion and necrosis in the liver, hypertrophy, and hypercholesterolemia in the heart, hydropic degeneration in the kidney, and no disturbance was found in the lung and spleen. Based on biochemical and histopathological result showed that cincalok had no toxic effect and potential to be developed as drug.

**KEYWORDS:** Blood biochemistry; Histopathology; Cincalok oil; Sub-chronic toxicity for 28 days; Wistar rats.

## 1. INTRODUCTION

Cincalok is a traditional food from West Kalimantan, Indonesia, which is made from a fermented mixture of Acetes shrimp, salt, and rice [1]. Cincalok has many beneficial contents, such as amino acid glutamic that important for brain function, palmitoleic fatty acids that can increase insulin sensitivity, omega-3 and omega-6 that important for organ nutrients, and astaxanthin as an antioxidant to prevent degenerative diseases [2-4]. Due to its beneficial ingredients such as amino acids (Glutamic Acid 1 085.438 mg 100 g<sup>-1</sup>), fatty acids (palmitoleic acid 27,170%, omega 3, omega 6) and astaxanthin 50,6590 µg/mL [2-5]; Cincalok has an opportunity to be developed into a supplement.

There is no information available on the dose and its relationship with the amount of cincalok consumption or possibly the dose of dietary supplements. However, this can be correlated with the astaxanthin content of cincalok as a supplement. The content of astaxanthin obtained per 100 g wet weight of cincalok in acetone solvent is 3.292 mg (cincalok fermentation 1 week), contains 0.920 mg (cincalok fermentation 2 weeks [6], and in VCO contains 50.6590±0.2502 µg per mL with maseration method [7] with the vortex method, the amount of astaxanthin extracted was 27.97 mg/g of dry weight of cincalok or 2.79 mg/mL VCO [8]. According to previous research, the dose of astaxanthin in cincalok as a food supplement is around 2 mg until 8 mg daily dose. In addition, cincalok can be consumed directly, used as a dipping sauce, and can also be combined with other foods such as chili sauce because cincalok can provide a savory taste to the sauce. In addition, cincalok can also be used as a starter in other fermented products because of the lactic acid bacteria found in these foods. In our previous study, LD<sub>50</sub> of cincalok oil was greater than 5000 mg/kg BW, suggesting that cincalok oil practically non-toxic [9]. However, an active substance can cause toxic effects on the body's organs when consumed in the long term and in repeated doses.

Cincalok oil has a high content of fatty acids, including palmitic acid, DHA, and EPA [10]. The fatty acids in cincalok, besides being efficacious, also make cincalok oil easily oxidized to form free radicals,

**How to cite this article:** Kurniawan H, Fajriaty I, Nurbaeti SN, Nugraha F, Deisberanda FS, Whidyastuti D. Sub-chronic Toxicity: Biochemical and Histopathological Profiling of Cincalok Oil in Wistar Rats. J Res Pharm. 2024; 28(4): 1253-1264.

which can damage body cells and increase the potential for diseases such as heart disease, high cholesterol, and cancer [11]. Therefore, this study was designed to find out the safety of cincalok oil through sub-chronic toxicity tests from biochemical and histopathological profiles so the effect of cincalok oil in long-term and repeated doses can be determined. Blood serum samples were analyzed for biochemical profiles because the biochemical components in the blood are very sensitive to the elements of toxicity contained in food, so if there is a deviation in the physiological status of an individual, the components and properties of the blood will change. Serum Glutamate Oxaloacetate Transaminase (SGOT) and Serum Glutamate Pyruvate Transaminase (SGPT) can be parameters of liver damage, creatinine and urea levels as parameters of kidney damage, also glucose, total cholesterol, triglyceride, HDL, and LDL levels as parameters of cardiovascular disease [12-13]. While for histopathological is performed to evaluate the effect of samples for organs such as liver, lung, hearth, kidney.

## 2. RESULTS

### 2.1. Sub-chronic toxicity study

There was no mortality in animals during the tests. The behavior activities have a bit change for the female rats in the group of 400 mg/Kg BW that in 30 minutes and 60 minutes, there was a decrease in the motor activity. However, this motor activity returned to normal after 120 minutes. The results of behavior activity in all groups of male rats were normal.

The evolution of body weight during the tests is shown in Figure 1 and Figure 2. The results showed an increase in body weight of all groups in both female and male rats. In the statistical analysis results, the significance value of body weight between groups of female and male rats was  $p > 0.05$ , which means there was no significant difference between all the rats' groups.

### 2.2. The Lipid Parameter of Biochemical Profiles

The results of biochemical serum parameters at the end of treatment are shown in Table 1 and Table 2. Data are expressed as mean  $\pm$  standard error of the mean (SEM).

**Table 1.** Effect of cincalok oil on biochemical serum lipid parameters

FEMALES RATS	Control	100 mg/KgBW	400 mg/KgBW	1000 mg/KgBW	Control Satellite	1000 mg/KgBW Satellite	Normal Range
Total Cholesterol	121.186 $\pm$ 9.62	126.594 $\pm$ 12.93	129.294 $\pm$ 7.07	115.202 $\pm$ 18.27	126.138 $\pm$ 5.23	108.650 $\pm$ 6.49 <sup>#</sup>	10-54 mg/dl
Triglycerides	178.628 $\pm$ 3.76	173.108 $\pm$ 4.54	172.924 $\pm$ 3.37	189.112 $\pm$ 18	189.762 $\pm$ 8.49	176.114 $\pm$ 6.30 <sup>#</sup>	10-54 mg/dl
HDL	61.372 $\pm$ 8.52	58.440 $\pm$ 8.74	63.480 $\pm$ 6.88	56.860 $\pm$ 8.76	61.200 $\pm$ 2.20	50.014 $\pm$ 8.79 <sup>#</sup>	$\geq$ 35 mg/dl
LDL	24.088 $\pm$ 13.35	33.532 $\pm$ 11.49	31.229 $\pm$ 8.38	20.519 $\pm$ 9.75	26.985 $\pm$ 4.83	23.413 $\pm$ 5.55	<27.2 mg/dl
MALES RATS	Control	100 mg/KgBW	400 mg/KgBW	1000 mg/KgBW	Control Satellite	1000 mg/KgBW Satellite	Normal Range
Total Cholesterol	113.224 $\pm$ 8.01	106.368 $\pm$ 6.38	112.056 $\pm$ 5.50	110.482 $\pm$ 6.66	110.862 $\pm$ 10.53	110.896 $\pm$ 12.11	10-54 mg/dl
Triglycerides	168.214 $\pm$ 10.62	177.084 $\pm$ 7.35 <sup>*</sup>	186.630 $\pm$ 2.65 <sup>*</sup>	183.120 $\pm$ 2.45 <sup>*</sup>	183.310 $\pm$ 3.63	184.426 $\pm$ 4.89	10-54 mg/dl
HDL	53.000 $\pm$ 2.03	46.360 $\pm$ 5.40 <sup>*</sup>	52.800 $\pm$ 3.93	54.320 $\pm$ 3.45	53.920 $\pm$ 7.47	55.620 $\pm$ 5.69	$\geq$ 35 mg/dl
LDL	26.581 $\pm$ 8.33	24.591 $\pm$ 11.09	21.930 $\pm$ 3.64	19.538 $\pm$ 9.08	20.280 $\pm$ 4.59	18.390 $\pm$ 8.64	<27.2 mg/dl

<sup>#</sup> P<0.05, significantly different versus satellite control,

<sup>\*</sup> P <0.05, significantly different versus control,

<sup>§</sup> P < 0.05, significantly different versus 1000 mg/kgBW control satellite

The results of measurements against lipid profiles can be seen in table 1. The administration of cincalok oil does not affect the HDL and LDL profiles because it is still within the normal value range. However, total cholesterol and triglyceride profiles were above the normal value range. The Post-Hoc analysis of LSD in female rats showed that long-term administration of cincalok oil, especially at doses 1000 mg/kg of BW cincalok oil, showed a reversible decrease in total cholesterol triglyceride and HDL profiles.

The statistical analysis of post-Hoc lipid profiles in male rats showed that long-term administration of cincalok oil could affect triglyceride profiles, increasing the profiles wherein the control group the TG profile is already above expected values.

### 2.3. The Glucose Parameter of Biochemical Profiles

The results of blood glucose profile measurement can be seen in table 2. All female and male rats' glucose profiles were above the normal value. The Post-Hoc analysis of LSD results in male and female rats showed that cincalok oil administration in female rats had a reversible decreased effect on glucose profiles.

**Table 2.** Effect of cincalok oil on biochemical serum glucose parameters

FEMALES RATS	Control	100 mg/KgBW	400 mg/KgBW	1000 mg/KgBW	Control Satellite	1000 mg/KgBW Satellite	Normal Range
Glucose	187.562±24.97	159.150±5.69*	179.552±31.15	165.658±32.48 <sup>s</sup>	167.844±3.58	127.984±5.18 <sup>#</sup>	50-135 mg/dl
MALES RATS	Control	100 mg/KgBW	400 mg/KgBW	1000 mg/KgBW	Control Satellite	1000 mg/KgBW Satellite	Normal Range
Glucose	145.748±160.62	141.544±4.65	134.344±5.79	131.600±6.48*	144.102±3.78	136.602±10.16	50-135 mg/dl

<sup>#</sup> P < 0.05, significantly different versus satellite control,

\* P < 0.05, significantly different versus control,

<sup>s</sup> P < 0.05, significantly different versus 1000 mg/kg control satellite

### 2.4. The Urea and Creatinine Parameter of Biochemical Profiles

The results of the measurement of the urea and creatinine profiles can be seen in table 3. The urea profiles in female rats showed a reversible decrease from crossing the normal range then back to the normal range. In contrast, in male rats, the administration of the 400 mg/Kg BW and 1000 mg/Kg BW doses of cincalok oil can increase the urea profile compared to the control but still in the normal range. The creatinine profiles in female rats showed that the administration of a dose of 1000 mg/Kg BW of cincalok oil could affect the creatinine profile in the form of a reversible decrease in female rats and a reversible increase in male rats.

**Table 3.** Effect of cincalok oil on biochemical serum urea and creatinine parameters

FEMALES RATS	Control	100 mg/KgBW	400 mg/KgBW	1000 mg/KgBW	Control Satellite	1000 mg/KgBW Satellite	Normal Range
Urea	51.756±5.28	53.292±7.62	49.664±2.07	51.322±6.92 <sup>s</sup>	39.718±1.3	39.824±5.13	10-50 mg/dl
Creatinine	0.998±0.05	0.922±0.11	0.904±0.16	0.960±0.10 <sup>\$</sup>	0.688±0.04	0.684±0.08	0.2-0.8 mg/dl
MALES RATS	Control	100 mg/KgBW	400 mg/KgBW	1000 mg/KgBW	Control Satellite	1000 mg/KgBW Satellite	Normal Range
Urea	41.642±3.24	44.742±2.62	49.334±2.12*	46.798±3.89*	49.816±0.89	45.222±2.90	10-50 mg/dl
Creatinine	0.702±0.11	0.770±0.02	0.702±0.09	0.760±0.09 <sup>s</sup>	0.876±0.05	0.898±0.02	0.2-0.8 mg/dl

<sup>#</sup> P < 0.05, significantly different versus satellite control,

\* P < 0.05, significantly different versus control,

<sup>\$</sup> P < 0.05, significantly different versus 1000 mg/kg control satellite

### 2.5. The SGOT and SGPT Parameter of Biochemical Profiles

The measurement results of the SGOT and SGPT profiles can be seen in table 4. The SGOT profiles in female and male rats showed that the administration of 1000 mg/Kg BW of cincalok oil had a reversible decrease effect in the SGOT profile. The long-term administration of cincalok can increase the SGPT in female rats for a dose of 1000 mg/Kg BW and in male rats for doses of 100 mg/Kg BW and 400 mg/Kg BW.

**Table 4.** Effect of cincalok oil on biochemical serum SGOT and SGPT parameters

FEMALES RATS	Control	100 mg/KgBW	400 mg/KgBW	1000 mg/KgBW	Control Satellite	1000 mg/KgBW Satellite	Normal Range
SGOT	72.862±16.70	83.064±11.59	85.738±15.11	71.286±8.27 <sup>§</sup>	73.896±9.43	52.408±14.70	45.70-80.80 U/L
SGPT	38.454±4.99	29.830±3.99	37.978±11.31	67.884±24.05	33.652±5.83	43.854±5.72	17.5-42.2 U/L
MALES RATS	Control	100 mg/KgBW	400 mg/KgBW	1000 mg/KgBW	Control Satellite	1000 mg/KgBW Satellite	Normal Range
SGOT	81.692±2.88	46.826±6.05*	77.220±11.37	71.038±8.00 <sup>§</sup>	55.454±12.75	45.670±7.52	45.70-80.80 U/L
SGPT	32.486±4.75	55.084±11.31*	43.366±8.72*	42.374±6.02	38.632±7.49	43.010±5.27	17.5-42.2 U/L

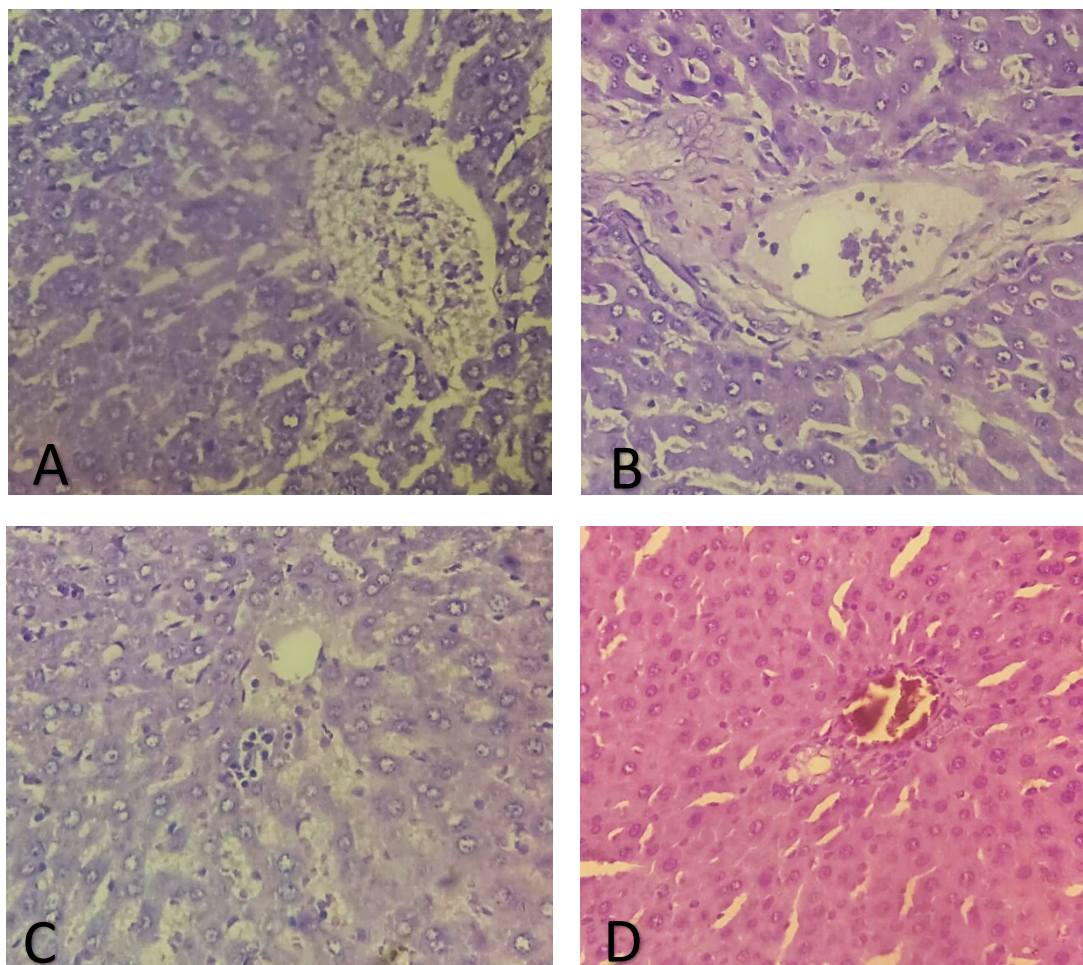
# P<0.05, significantly different versus satellite control,

\* P <0.05, significantly different versus control,

§ P < 0.05, significantly different versus 1000 mg/kg control satellite

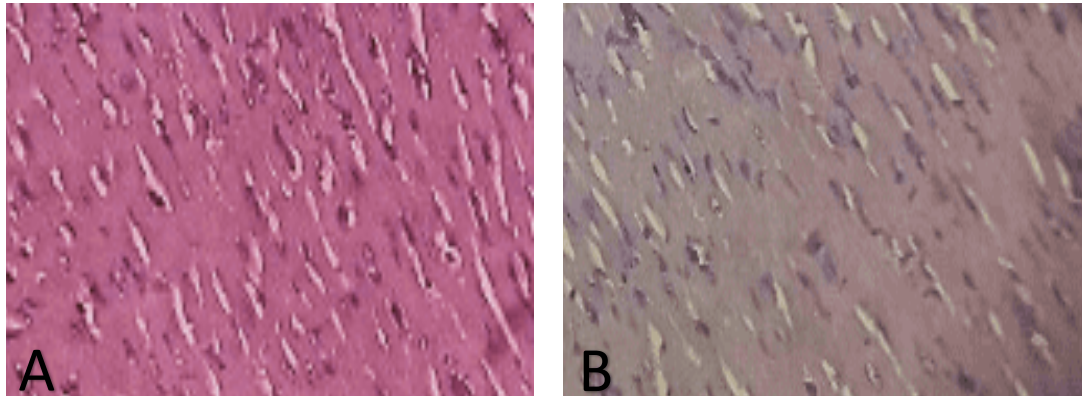
## 2.6. Histopathological investigation

Cincalok oil had an effect on the histological profile of the liver in the form of minimum fat degeneration in all test groups. Degeneration with slight central venous congestion occurred in the female group at dose of 400mg / Kg BW and dose of 100mg / Kg BW. Necrosis occurred in the female group with doses above 1000 mg / Kg BW and the male group with doses below 100 mg / Kg BW (Figure 1).

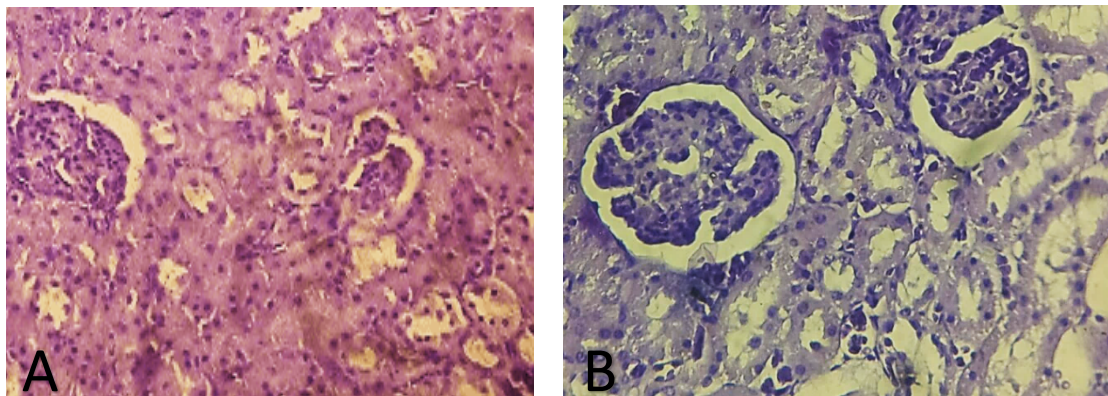


**Figure 1.** Representative of microscopic changes in Rat's liver after treatment with cincalok oil, magnification scale: x 40. A: Lower dose 100 mg/KgBW; B: Middle dose 400 mg/KgBW; C: Upper dose 1000 mg/KgBW; D: Satellite of upper dose 1000 mg/KgBW.

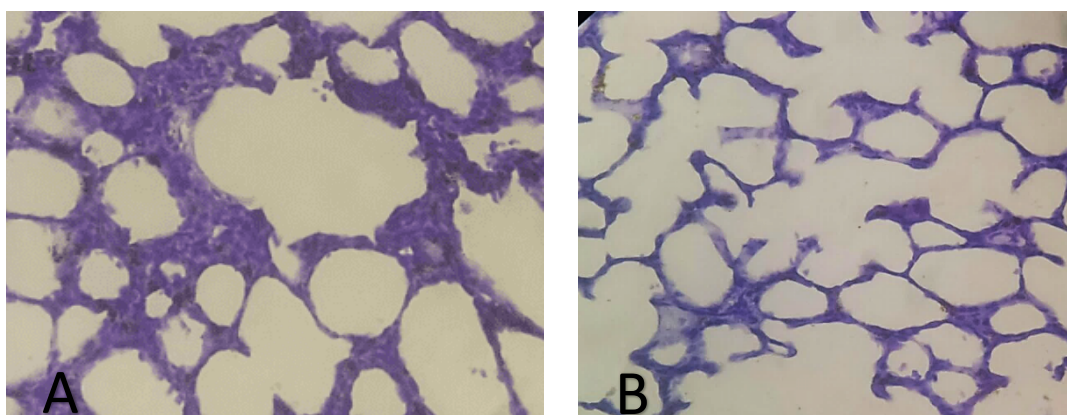
Cincalok oil also has effects on the histological profile of the heart in the form of hypertrophy and hypercholesterolemia in the female group at doses of over 1000mg / Kg BW which are irreversible (Figure 2), and on the histological profile of the kidneys in the form of hydropic degeneration in the female and male groups at doses of 1000 mg / Kg BW which are reversible (Figure 3). However, cincalok oil had no effect on the histological profile of other organs including lung, kidneys and limpha showed no sign of pathological change compared with the corresponding organ of the controls (Figure 4 and Figure 5).

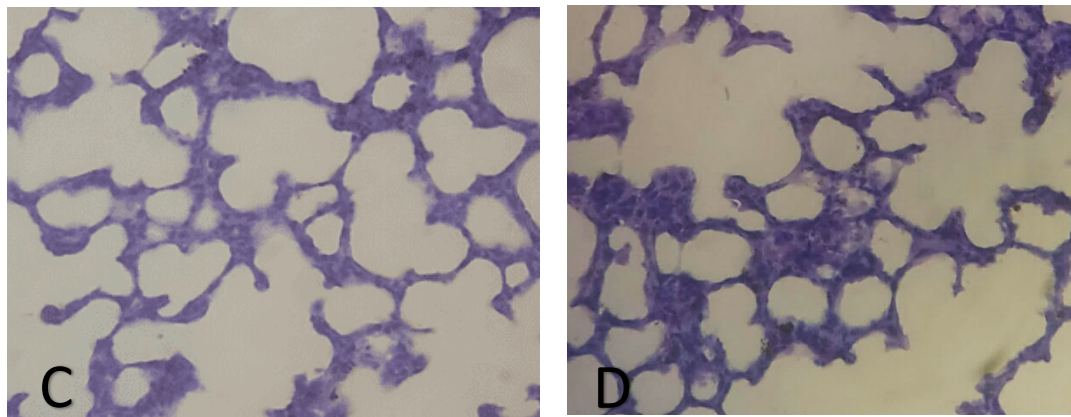


**Figure 2.** Representative of microscopic changes in Rat's heart after treatment with cincalok oil, magnification scale: x 40. A: Upper dose 1000 mg/KgBW; B: Satellite of upper dose 1000 mg/Kg BW.

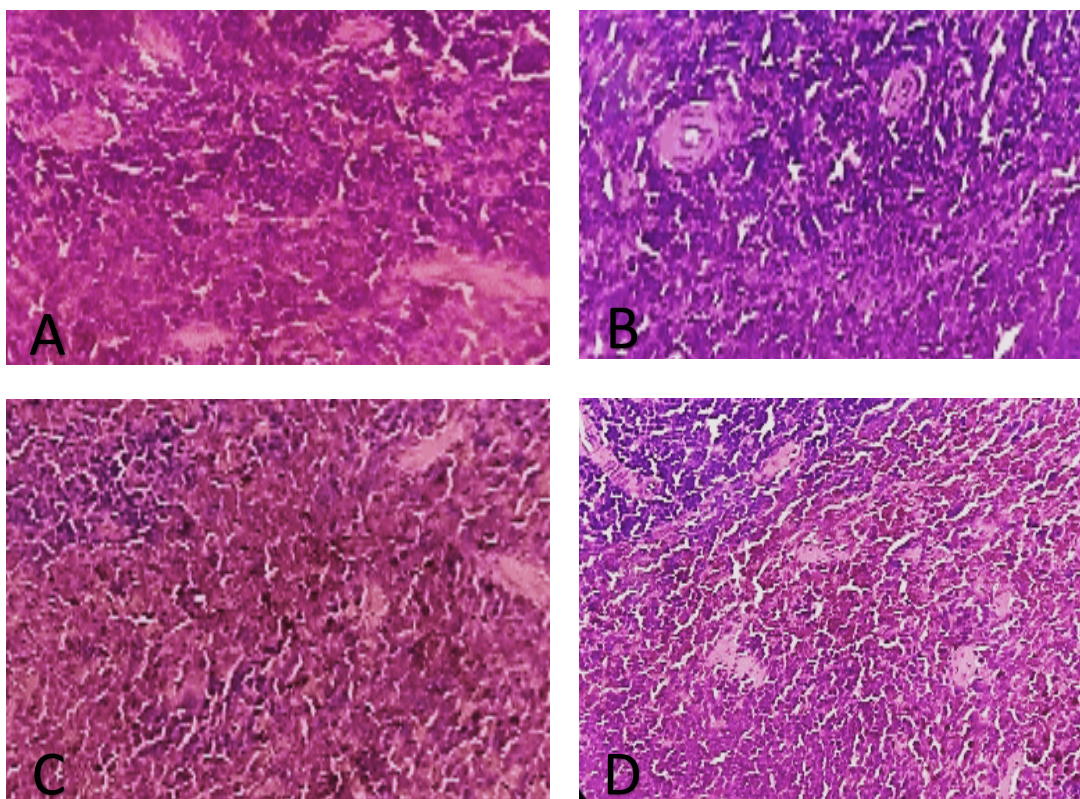


**Figure 3.** Representative of microscopic changes in Rat's kidney after treatment with cincalok oil, magnification scale: x 40. A: Upper dose 1000 mg/KgBW; B: Satellite of upper dose 1000 mg/Kg BW.





**Figure 4.** Representative of microscopic changes in Rat's lung after treatment with cincalok oil, magnification scale: x 40. A: Lower dose 100 mg/KgBW; B: Middle dose 400 mg/KgBW; C: Upper dose 1000 mg/KgBW; D: Satellite of upper dose 1000 mg/KgBW.



**Figure 5.** Representative of microscopic changes in Rat's spleen after treatment with cincalok oil, magnification scale: x 40. A: Lower dose 100 mg/KgBW; B: Middle dose 400 mg/KgBW; C: Upper dose 1000 mg/KgBW; D: Satellite of upper dose 1000 mg/KgBW.

### 3. DISCUSSION

Based on the study's results, the administration of cincalok oil had a normal effect on activity and motor behavior during an examination, except for female rats. A decrease in motor activity occurred at 30 and 60 minutes in the female rat group with a moderate dose of 400 mg/kg BW but returned to normal in 120 minutes. Guo et al., in their study of motor performance in relation to age, anthropometric characteristics, and serum lipids in women, showed that high triglycerides and low HDL cholesterol were associated with poor motor performance in women[14]. This is in accordance with the results, which will be discussed later, which found that serum lipid parameters were higher in female rats than male rats. Therefore, it is suspected that there is a decrease in motor activity in female rats.

In addition, the administration of cincalok oil affects the rats' growth from an increase in body weight during tests. Increased body weight was thought of because of omega-6 and omega-3 fatty acid compounds contained in cincalok oil. In several previous studies, omega-6 was said to have an important role in linear growth in children with functions to modulate various physiological responses such as growth cells and differentiation in altered cell proliferation conditions [15-16]. Omega-3 also has a beneficial role in bone metabolism by increasing bone formation, reducing bone loss, and increasing calcium levels, contributing to growth in children [15]. Other factors such as the amount of food intake and growing rats' process can also cause weight gain.

In lipid profiles, the results of total cholesterol and triglyceride profiles were above the normal value range, presumably because VCO as a control contained 90% saturated fatty acids. Excessive consumption of saturated fat can stimulate the liver to produce more cholesterol [17]. In Yuiwanti's study (2018), VCO increased cholesterol levels compared to controls because VCO contains more than 50% lauric acid, which will release additional energy when passing through the hepatic artery. The energy gain from VCO made the VCO group in that study did not seek energy addition through lipid catabolism, which would increase cholesterol and LDL levels in the group [18]. The reversible decrease in total cholesterol triglyceride and HDL profiles in female rats is suspected to be due to Astaxanthin's content, which has antioxidant activity which can inhibit lipid peroxidation [19]. Astaxanthin and its esters showed 80% anti-lipid peroxidation activity in ethanol induced gastric ulcer rats (dose: 500 µg/Kg BW) and skin cancer rats (dose: 200 µg/Kg BW) [20-21]. Previous studies found that astaxanthin 30mg/Kg BW can reduce liver triglycerides, plasma triglycerides, and total cholesterol in obese rats [22]. Astaxanthin also has cardioprotective activity through its ability to reduce HDL oxidation so that the amount of HDL in the plasma increases [23-24]. Differences in triglyceride profiles in male and female rats are suspected to be due to the role of the hormone estrogen in female rats. Estrogen can inhibit the action of the enzyme Lipoprotein Lipase (LPL), which is responsible for breaking down triglycerides to be stored in adipose tissue as reserve energy. Estrogen can also increase the production of epinephrine, thus increasing the activity of the lipase-sensitive hormone, which plays a role in triglyceride lipolysis, which causes triglyceride levels in the blood to decrease [25]. Estrogen also protects the body through its activity as an antioxidant, so it has a synergistic action with astaxanthin [26]. Therefore, statistical results in female rats had triglyceride reductions but not in male rats.

In glucose profiles, all female and male rats' glucose profiles were above the normal value range is suspected because VCO control has a role because it has free fatty acids, which can stimulate gluconeogenesis and inhibit glucose absorption by skeletal muscles, thereby increasing the amount of glucose in the blood. Narayanankutty's research (2016) also found that people given a VCO diet experienced increased blood glucose levels even though they were only 17% lower than other treatments [27]. The release of glucose profiles in male and female rats is associated with astaxanthin as an antioxidant. The condition hyperglycemia is usually associated with diabetes mellitus. In the Wahyu's study, astaxanthin can reduce diabetes complications through free radical capture mechanisms, reduce oxidative stress, reduce  $\alpha$  expression of TNF [28]. Palmitoleic acid is also suspected of having a role in this case because it improves insulin sensitivity by suppressing inflammation and inhibiting the destruction of pancreatic beta cells that secrete insulin [2].

The creatinine profile above the normal range in blood in male rats can indicate impaired kidney function. This can be caused by several conditions, including the presence of fatty acids in the VCO as a control. High levels of fatty acids can cause atherosclerosis and a decrease in the speed of blood flow which causes a reduced blood supply to the kidneys. This causes a decrease in kidney function [29].

The reversible decrease effect in the SGOT profile is suspected to be due to Astaxanthin as an antioxidant that can prevent damage to liver cell membranes. Hence, SGOT enzyme levels decrease because they do not come out into the blood circulation [30]. The increased profile of SGPT can be caused by fatty acid compounds that will undergo metabolism in the liver and be distributed throughout the body in the form of energy, cholesterol, and fat deposits. Fat accumulation can increase the lipid peroxidation chain reaction, increasing SGPT enzyme [30]. The SGPT enzyme increase in this test is still within the normal range, so it cannot be said to indicate liver damage.

In this study, some values outside the normal range were thought to be effects of VCO as control. VCO was initially chosen as a solvent because some previous studies have found that VCO can dissolve large amounts of Astaxanthin [31-32]. VCO was also chosen because it is environmentally friendly vegetable oil, has abundant availability, and is affordable compared to organic solvents [33]. However, it turns out that in this study, some biochemical profiles have values beyond the normal range allegedly because VCO as control has a free fatty acid. Therefore, it is recommended not to use this solvent in subsequent studies.

The microscopic appearance of central veins and hepatocytes on histopathological examination differed from the control group. The histological condition of the liver is characterized by vacuolation,

variations in the shape and size of the nucleus in hepatocytes, loss of sinusoidal spaces, and inflammatory cells spreading throughout the liver tissue. There will be dilation of the liver tissue, and there will be widening of the central tissue vein full of blood. There were Kupffer cells in the sinusoidal spaces, which showed no pathological changes in the liver. However, there is minimal fatty degeneration in the histological profile of the liver found in all test groups. This degeneration belongs to the minimal type that does not really affect the existing cell structure and can occur due to an increase in free fatty acids, reduced oxidation of free fatty acids, and reduced export of triglycerides due to a deficiency of fat-binding apoproteins. Excessive fat intake, thought to originate from the test preparations that are given continuously, can cause hypercholesterolemia, which has an impact on the imbalance of bile acid synthesis in the liver in synthesizing cholesterol, resulting in oxidative stress, which triggers the formation of free radicals in the liver tissue. The degeneration that causes mild congestion occurs in the medium and low dose groups of female rats and is characterized by the expansion or enlargement of the central vein. Congestion due to circulatory disorders is also one of the manifestations of high levels of LDL cholesterol in the blood produced by the liver due to high consumption of saturated fat from cincalok oil, which causes thrombosis and disrupts blood circulation. This study also found necrosis, but it was relatively normal in small amounts. Clinically, fatty liver degeneration and congestion due to high fat consumption, especially saturated fat, are associated with an increased incidence of heart disease and thrombosis.

Microscopic observation of heart preparations showed disturbances in hypertrophy and hypercholesterolemia in several groups. Hypercholesterolemia is characterized by irregular changes in cardiomyocyte structure, which is the initial stage of necrosis, while the thickening of myocytes characterizes hypertrophy. Hypertrophy from hypercholesterolemic conditions is thought to be due to the fatty acid content in cincalok oil, as mentioned in the case of hypercholesterolemia that occurred in previous liver histology. Cincalok oil has no effect on the histological profile of other organs, including the lungs, kidneys, and spleen, which show no signs of pathological changes compared to the corresponding control organs.

#### 4. CONCLUSION

Based on the results of the current study, we may conclude that the long-term administration of cincalok has no effect on LDL, urea, creatinine, Serum Glutamate Oxaloacetate Transaminase, and Serum Glutamate Pyruvate Transaminase blood profiles. While on total cholesterol, triglycerides, and HDL profiles, it has reversible effect. As a whole, cincalok oil has no effect on the histological profile of the lung and spleen organs, but has an influence on the histological profile of the liver, heart and kidneys.

Degeneration with slight central venous congestion occurred in the female rats at 400 mg/kg BW doses and 100 mg/kg BW doses, while necrosis occurred in the female rats at doses 1000 mg/kg BW and in the male rats at doses 100 mg/kg BW. Cincalok oil affects the histological profile of the heart in the form of hypertrophy and hypercholesterolemia in female rats with doses of 1000 mg/kg BW. Therefore further research is needed at smaller doses to see the potential for cincalok oil as a supplement with higher safety.

#### 5. MATERIALS AND METHODS

##### 5.1. Materials

The dried cincalok was obtained from Singkawang City, West Kalimantan, Indonesia. VCO (Virgin Coconut Oil) was purchased from SOFIA, Indonesia. The reagents used in this study were 96% alcohol, acetic acid, picric acid, EDTA (Ethylenediaminetetraacetic Acid), chloroform, potassium iodide, sodium thiosulfate ( $\text{Na}_2\text{S}_2\text{O}_3$ ), eosin, formalin buffer solution, paraffin, hematoxylin dyes, and xylol, which were purchased from Sigma Aldrich. The glucose examination reagent, HDL examination reagent, LDL examination reagent, cholesterol examination reagent, creatinine examination reagent, SGOT examination reagent, SGPT examination reagent, triglyceride examination reagents, and urea examination reagents were purchased from Human Diagnostic Worldwide.

##### 5.2. Preparation of cincalok oil

The Cincalok was obtained from Singkawang City, West Kalimantan, Indonesia. Wet cincalok was filtered, and the residue was dried at 50°C for 3 hours using a vacuum dryer. It was ground using a blender to become a fine powder. Cincalok fine powder was soaked using the VCO solvent, and it was ground again for 30 minutes. The mixture was filtered after 24 hours passed [34].



### 5.3. Experimental animals

The experimental animal protocols in this study were authorized by the Animal Ethics Committee of Medicine Faculty, Universitas Tanjungpura, West Kalimantan (number of ethical clearance: 6628/UN22.9/TA.00.03/2019). Animal subjects that used in this research were female and male Wistar rats (*Rattus norvegicus*), aged 6-8 weeks, weighing 150-250 g (no weight variation more than 20%), not pregnant, not disabled/have any physical and anatomical abnormalities, no appearance of dull, falling, or bald hair and did not experience significant weight loss during acclimatization. The rats were fed and given water ad libitum, also maintained under laboratory conditions [35-36].

### 5.4. Sub-chronic toxicity study

The animals were given Virgin Coconut Oil (VCO) for the control group, cincalok oil with dose variation of 100, 400, and 1000 mg/kg BW for the dosing groups, and 1000 mg/kg dose of cincalok oil and VCO for two satellite groups every day for 28 days. The physical conditions and behavior of each animal were monitored daily during the 28 days study. The body weight was measured every day. The satellite groups were then left for 14 days without being given VCO or cincalok oil, only given food and drink, and monitored daily for physical conditions, behavior, and body weight. Surgery was performed on the 29th day for the control group and dosing groups, whereas the satellite groups were performed on the 43rd day. Shortly before surgery, after the mice were killed, rat blood samples in each group were collected into Eppendorf tubes without anticoagulant and then centrifuged for 10 minutes at 1400 rpm resulting in the serum taken for biochemical analysis. The organs (liver, spleen, kidney, lung, and heart) that were taken from the animal were washed and immersed in a formalin buffer solution [35-36].

### 5.5. Serum biochemical analysis

The biochemical profiles of blood, including total cholesterol, triglycerides, HDL, LDL, glucose, urea, creatinine, SGOT, and SGPT, were determined with a spectrophotometer blood analysis.

#### 5.5.1. Examination of Total Cholesterol Levels

A total of 5  $\mu$ L of blood serum was put into a tube containing 500  $\mu$ L of cholesterol test reagent, then incubated as an endpoint for  $\pm 5$  minutes at 37°C. The absorbance of the sample and the standard were measured at a wavelength of 546 nm. This analysis uses the "CHOD-PAP" method which is an enzymatic photometric test [37].

#### 5.5.2. Examination of Triglyceride Levels

A total of 5  $\mu$ L of blood serum was put into a tube containing 500  $\mu$ L of the triglyceride test reagent, then incubated as an endpoint for  $\pm 5$  minutes at 37°C. The absorbance of the sample and the standard were measured at a wavelength of 546 nm. This analysis uses the enzymatic colorimetric testing method using the "GPO-PAP" method [37].

#### 5.5.3. Examination of HDL Levels

A total of 100  $\mu$ L of serum was added to 200  $\mu$ L of HDL precipitate, then centrifuged. 50  $\mu$ L of the clear part was taken, mixed with 500  $\mu$ L of cholesterol test reagent, then incubated at 37°C for 5 minutes. The absorbance of the sample and the standard were measured at a wavelength of 578 nm. HDL levels were measured using the Colorimetric Test method with a UV-Visible spectrophotometer [37].

#### 5.5.4. Examination of LDL Levels

Determination of Low-Density Lipoprotein (LDL) is carried out by indirect calculation using the

$$\text{LDL} = \text{TC} - \left( \frac{\text{TG}}{5} + \text{HDL} \right)$$

Friedewald formula [38]:

TC = Total Cholesterol

TG = Triglycerides  
HDL = High Density Lipoprotein

#### 5.5.5. Examination of Blood Glucose Levels

Measurements were taken one day after the last administration of the cincalok oil (same as the fasting blood glucose measurements, where blood glucose measurements were taken after fasting for 8–12 hours before testing to describe the glucose level produced in the liver in rat blood serum).. A total of 5  $\mu$ L of blood serum was put into a tube containing 500  $\mu$ L of the glucose test reagent, then incubated as an endpoint for  $\pm$ 5 minutes at 37°C. The absorbance of the sample and the standard were measured at a wavelength of 340 nm. This analysis uses the "GOD-PAP" method which is an enzymatic photometric test [37].

#### 5.5.6. Examination of Urea Levels

5  $\mu$ L of blood serum was put into a tube containing 500  $\mu$ L of the first urea test reagent, then incubated as an end point for  $\pm$ 5 minutes at 37°C. The second urea reagent was then added. The absorbance of the sample and the standard were measured at a wavelength of 578 nm. This analysis uses the Berthelot method, which is an enzymatic colorimetric test [37].

#### 5.5.7. Examination of Creatinine Levels

A total of 25  $\mu$ L of blood serum was put into a tube containing 250  $\mu$ L of the creatinine test reagent, then mixed and incubated in the apparatus for 5 minutes at 25°C. The absorbance of the sample and the standard were measured at a wavelength of 510 nm. This analysis uses the Jaffe method [37].

#### 5.5.8. Examination of SGOT and SGPT Activity

A total of 50  $\mu$ L of blood serum was put into each tube containing 500  $\mu$ L of the SGPT examination reagent and 500  $\mu$ L of the SGOT examination reagent, mixed and incubated in the apparatus for 5 minutes at 25°C. The absorbance of the sample and the standard were measured at a wavelength of 340 nm. This analysis uses the UV test method [37].

#### 5.6. Microscopic Analysis of the Organs

The organs that stored in a formalin buffer solution then embedded in paraffin. Slicing was conducted using a microtome and stained with hematoxylin and eosin, then observed using a microscope [39].

#### 5.7. Histopathological investigation

The histopathological investigation was accorded to the method described in the literature [40]. Tissue samples were prepared routinely and cut into two  $\mu$ m slides, and tissues were subjected to dehydration, embedded in paraffin, sectioned at 3-5 microns, followed by hematoxylin-eosin staining. The pathological observation of all tissue was performed on gross and microscopic bases then examined using a light microscope [39].

#### 5.8. Statistical analysis

The results of biochemical of blood parameters were analyzed using the One Way ANOVA followed by Post-Hoc Least Significant Difference (LSD) to compare any significant differences ( $p \leq 0.05$ ) in each group.

**Acknowledgements:** Thanks to Universitas Tanjungpura, which has funded this research, and the Clinical and Pharmacology Laboratory, Faculty of Pharmacy, Universitas Tanjungpura.

**Author contributions:** All authors have contributed substantially in arranged and revised the article and have agreed to submit this journal, giving final approval of the version to be published. They also agreed to be responsible for all aspects of the job.

**Conflict of interest statement:** All the authors declare that they have no conflicts of interest.

## REFERENCES

- [1] Nofiani R, Puji A. Physicochemical and Microbiological Profiles of Commercial Cincalok from West Kalimantan. *Jurnal Pengolahan Hasil Perikanan Indonesia*. 2018; 21(2): 243–249. <https://doi.org/10.17844/jphpi.v21i2.22851>
- [2] Khairina R, Fitriani Y, Satrio H, Rahmi N. Physical, Chemical, and Microbiological Properties of 'Ronto' a Traditional Fermented Shrimp from South Borneo, Indonesia. *Aquat Procedia*. 2016; 7:214–220. <https://doi.org/10.1016/j.aqpro.2016.07.029>
- [3] Yonata A, Iswara I. Efek Toksik Konsumsi Monosodium Glutamate. *Majority*. 2016; 5(3): 100–104.
- [4] Ngginak J, Semangun H, Mangimbulude JC, Rondonuwu FS. Komponen Senyawa Aktif pada Udang Serta Aplikasinya dalam Pangan. *Sains Med*. 2013; 5(2): 128–145. [10.30659/sainsmed.v5i2.354](https://doi.org/10.30659/sainsmed.v5i2.354)
- [5] Risnawati N, Nurbaeti SN, Kurniawan H. Pengaruh Variasi Konsentrasi Karaginan Kombinasi Emulgator Anionik dan Nonionik Terhadap Formulasi Losion Astaxanthin Ekstrak Minyak Cincalok. *J. Sains dan Kesehat*. 2021; 3(2): 101–109. <https://doi.org/10.25026/jsk.v3i2.272>
- [6] Nurbaeti SN, Faradilla A, Kurniawan H, Fajriaty I, and Nugraha F. Penetapan Kadar Astaxanthin Dalam Cincalok Yang Difermentasi. *J. Farm. Udayana*. 2022; 11(1): p. 32. <https://doi.org/10.24843/JFU.2022.v11.i01.p06>
- [7] Aprianti I, Nurbaeti, and H. Kurniawan. Formulasi Sediaan Emulsi Mengandung Astaxanthin dari Ekstrak Minyak Virgin Coconut Oil Cincalok. *J. Syifa Sci. Clin. Res*. 2022.4 (1): 190–201. <https://doi.org/10.37311/jsscr.v4i1.13635>
- [8] Fitriani D, Rahmalia W, Ardiningsih P, Usman T, Nurbaeti SN, and Prayitno DI. Extraction of astaxanthin from fermented Acetes using virgin coconut oil with the glass beads vortex method. *OCL - Oilseeds fats, Crop. Lipids*. 2023; 30(1). <https://doi.org/10.1051/ocl/2023002>
- [9] Nurbaeti SN, Fajriaty I, Nugraha F, Kurniawan H, Rahmalia W, Usman T, Prayitno DI. Acute Oral Toxicity of Cincalok Oil in Wistar Rats. *Indonesian Journal of Pharmaceutical Science and Technology*. 2021; 8(2):51. <https://doi.org/10.24198/ijpst.v8i2.26343>
- [10] Rahmalia W, Dasilia C, Usman T, Prayitno DI, and Nurbaeti SN. Astaxanthin and omega-3-rich oil from fermented Acetes (Cincalok) and its application as bioactive additive and sunscreen in lotion. *OCL - Oilseeds fats, Crop. Lipids*, 2022; 29:1–8. <https://doi.org/10.1051/ocl/2022012>
- [11] C. Sandra, *Terapi Liver Diet Sehat Pembersih Liver*. Jakarta: Mitra Media, 2007.
- [12] Hendrarti W, Indrisari M, Pasang M, Nursamsiar N. Uji Toksisitas Subkronik Ekstrak Etanol daun Jati Putih (*Gmelina arborea* Roxb.) pada Tikus Putih Jantan (*Rattus novergicus*). *Pharmacy: Jurnal Farmasi Indonesia*. 2012; 9(3): 33–41. <https://doi.org/10.30595/pji.v9i3.738>
- [13] Helmanu K, Ulfa N. *STOP! Diabetes, Hipertensi, Kolesterol Tinggi, Gejala Penyakit Jantung Koroner*. Jakarta: Istana Media. 2015.
- [14] Guo X, Matousek M, Sundh V, and Steen B. Motor performance in relation to age, anthropometric characteristics, and serum lipids in women. *Journals Gerontol. - Ser. A Biol. Sci. Med. Sci*. 2022; 57(1): 37–44. <https://doi.org/10.1093/gerona/57.1.M37>
- [15] Adjepong M, Yakah W, Harris WS, Colecraft E, Marquis GS, Fenton JI. Association of Whole Blood Fatty Acids and Growth in Southern Ghanaian Children 2 – 6 Years of Age. *Nutrients*. 2018; 10(8): 954. <https://doi.org/10.3390/nu10080954>
- [16] Simopoulos AP. A High Omega-6 / Omega-3 Fatty Acid Ratio Increases the Risk for Obesity. *Intervention Obesity Diabetes*. 2018; 1(2): 28–36.
- [17] Susilowati S. Pembuatan Virgin Coconut Oil Dengan Metode Penggaraman. *Jurnal Teknik Kimia*. 2009; 3(2): 246–251.
- [18] Yuiwanti EYW, Saraswati TR, Kusdiyantini E. Effect of VCO and olive oil on HDL, LDL, and cholesterol level of hyperglycemic *Rattus Rattus Norvegicus*. *Journal of Physics: Conf. Series*. 2018; 1025(1).
- [19] Ambati RR, Moi PS, Ravi S, Aswathanarayana RG. Astaxanthin: Sources, extraction, stability, biological activities and its commercial applications - A review. *Mar Drugs*. 2014; 12(1): 128–152. <https://doi.org/10.3390/md12010128>
- [20] Rao AR, Baskaran V, Sarada R, Ravishankar GA. In vivo bioavailability and antioxidant activity of carotenoids from microalgal biomass - A repeated dose study," *Food Research International*. 2013; 54(1): 711–717. <https://doi.org/10.1016/j.foodres.2013.07.067>
- [21] Kamath BS, Srikanta BM, Dharmesh SM, Sarada R, Ravishankar GA. Ulcer preventive and antioxidative properties of astaxanthin from *Haematococcus pluvialis*. *European Journal Pharmacology*. 2008; 590(1-3): 387–395. <https://doi.org/10.1016/j.ejphar.2008.06.042>
- [22] Choi HD, Kim JH, Chang MJ, Youn YK, Shin WG. Effects of Astaxanthin on Oxidative Stress in Overweight and Obese Adults. *Phyther. Res*. 2011; 25(12): 1813–1818. <https://doi.org/10.1002/ptr.3494>
- [23] Capelli B, Cysewski G. *ASTAXANTHIN (Natural Astaxanthin: King of The Carotenoids)*. Hawaii: Cyanotech Corporation, 2007.
- [24] Ifah M, Thamrin W. Astaxanthin: senyawa antioksidan karoten bersumber dari biota laut. *Squalen*. 2006; 1(1): 1–5. <https://doi.org/10.15578/squalen.71>
- [25] Chantal V, Len K. Gender differences in fat metabolism. *IDEA Heal. Fit. Source*. 2002; 20(10).
- [26] Cervellati C, Bergamini CM. Oxidative damage and the pathogenesis of menopause related disturbances and diseases. *Clin. Chem. Lab. Medicine*. 2016; 54(5): 1–15. <https://doi.org/10.1515/cclm-2015-0807>
- [27] Narayanankutty A, Mukesh RK, Ayoob SK, Ramavarna SK, Suseela IM, Manalil JJ, Kuzhivelil BT, Raghavamenon AC. Virgin coconut oil maintains redox status and improves glycemic conditions in high fructose fed rats. *J. Food Sci. Technol*. 2016; 53(1): 895–901. [10.1007/s13197-015-2040-8](https://doi.org/10.1007/s13197-015-2040-8)

- [28] Wahyu W. Potensi antioksidan sebagai antidiabetes. JKM. 2008; 7(2): 1-11.
- [29] Sabarudin A, Wulandari ERN, Sulistyarti H. Sequential Injection-Flow Reversal Mixing (SI-FRM) untuk penentuan kreatinin dalam urin. J. MIPA. 2012; 35(2): 157-164. <https://doi.org/10.15294/ijmns.v35i2.2627>
- [30] Arif H, Wulan C, Aditya M. Pengaruh vitamin E terhadap kadar SGPT dan SGOT tikus putih galur Wistar yang dipapar timbal. Unnes J Life Science. 2013; 2(1): 16-21.
- [31] Panicha P, Supatra N, Itthayakorn P. Antimicrobial Activities of Vegetable Oil-Extracted Astaxanthin From Microalgae *Haematococcus pluvialis*. 1st Mae Fah Luang Univ. Int. Conf. 2012: 1-8.
- [32] Sindhu S, Sherief PM. Extraction , Characterization , Antioxidant and Anti-Inflammatory Properties of Carotenoids from the Shell Waste of Arabian Red Shrimp *Aristeus alcocki* , Ramadan 1938. Open Conf. Proc. J. 2011; 2: 95-103. 10.2174/2210289201102010095
- [33] Handayani AD, Sutrisno, Indraswati N, Ismadji S. Extraction of astaxanthin from giant tiger ( *Panaeus monodon* ) shrimp waste using palm oil : Studies of extraction kinetics and thermodynamic. Bioresour. Technol. 2008; 99: 4414-4419. <https://doi.org/10.1016/j.biortech.2007.08.028>
- [34] Prayitno DI, Nurdiansyah SI, Nurbaeti SN, Rahmalia W, Usman T. Ekstraksi dan Analisis Astaxanthin dari Cincalok dengan Variasi Minyak Nabati. Pertem. Ilm. Nas. Tah. XV ISOI 2018: 165-169.
- [35] BPOM Republik Indonesia. Keputusan Kepala Badan Pengawas Obat dan Makanan Nomor: HK.00.05.4.2411 tahun 2004 tentang Ketentuan Pokok, Pengelompokan dan Penandaan Obat Bahan Alam Indonesia. 2004.
- [36] OECD/OECD. Test No. 407: Repeated dose 28-day oral toxicity study in rodents. OECD Guidelines for the Testing of Chemical. 2008: 1-13.
- [37] DEPKES Republik Indonesia, Keputusan Menteri Kesehatan RI Nomor 1792 tentang Pedoman Pemeriksaan Kimia Klinik. Indonesia, 2010.
- [38] P. L. Vieira et al., "Low-Density Lipoprotein Values Estimated by Friedewald Equation are Affected by Diabetes Control," Int. J. Cardiovasc. Sci., vol. 29, no. 5, pp. 348-354, 2016. <https://doi.org/10.5935/2359-4802.20160045>
- [39] S. IK, Teknologi ilmu jaringan dan imunohistokimia. Jakarta: Sagung Seto, 2005.
- [40] Abd-Elhamid HF. Investigation of induced biochemical and histopathological parameters of acetonitril extract of *Jatropha carcus* in albino rats. J. Egypt. Soc. Parasitol. 2004; 34(2): 397-406.

This is an open access article which is publicly available on our journal's website under Institutional Repository at <http://dspace.marmara.edu.tr>.