

Evaluation of the teratogenic effect of water extract of *Sonchus arvensis* L. and *Anredera cordifolia* (Ten.) Steenis leaves as a combination in Wistar rat

Nova SULISKA¹ , Sinar Kasih MENTARI¹ , Elin Yulinah SUKANDAR^{1,2*} 

¹ Department of Pharmacology-Clinical Pharmacy, School of Pharmacy, Institut Teknologi Bandung, Bandung, Indonesia

² Department of Pharmacology, Faculty of Pharmacy, University of Jenderal Achmad Yani, Cimahi, Indonesia

* Corresponding Author. E-mail: eyulinah@gmail.com Tel. +62-022-8990356323.

Received: 12 October 2021 / Revised: 28 May 2022 / Accepted: 30 May 2022

ABSTRACT: Water extract of *Sonchus arvensis* and *Anredera cordifolia* leaves as a combination has been proven for their antihypertensive activity, but there is no information about its safety for pregnant women yet. This experiment aimed to evaluate the teratogenic effect of water extract of *S. arvensis* and *A. cordifolia* leaves as a combination (1:1) at doses of 100 mg/kg bw, 400 mg/kg bw, and 1000 mg/kg bw in Wistar rats. The extract was made into suspension in sodium carboxymethyl cellulose (Na-CMC) 0.5% and given orally to pregnant rats on gestation day 6-15 as much as 1 mL/100 gram bw. Pregnant rats were sacrificed at gestation day 19. All parameters related to fetuses included the number of fetuses, fetal weight, skeletal and organ malformation were evaluated. The percentage of skeletal and organ malformation of each treatment groups was compared to the control group and analyzed with one-way ANOVA method using IBM SPSS 28. There was no significant difference in both average number and fetal weight from all treatment groups compared to the control group ($P>0.05$). Skeletal malformation was not found, but there were undeveloped fetuses (resorption) and some fetuses with small brains in all groups. The percentage of each treatment groups for those two conditions was not significantly different compared to the control group. Therefore, water extract of *S. arvensis* and *A. cordifolia* leaves as a combination at doses of 100 mg/kg bw, 400 mg/kg bw, and 1000 mg/kg bw contraindicated for pregnant women and those who are planning on pregnancy.

KEYWORDS: *S.arvensis*; *A.cordifolia*; water leaves extract; antihypertensive activity; teratogenic effect.

1. INTRODUCTION

According to the Medicinal Plants Database, there are about 30,000 species of medicinal plants in Indonesia out of 40,000 known worldwide [1]. Of these, only 1,000 species have been used as raw material for herbal medicines or traditionally as jamu (traditional Indonesian drink), such as *Sonchus arvensis* and *Anredera cordifolia*. The leaves of *S. arvensis* and *A. cordifolia* are traditionally used to treat kidney stones, to aid in the wound healing process, and to relieve fatigue and pain [2-4]. The leaves of *A. cordifolia* contain several secondary metabolites such as flavonoids (apigenin, apigethrin, vitexin, isovitexin), terpenoids, steroids, glycosides, and alkaloids [5], which contribute to their pharmacological effects, including anti-obesity [6] and inhibitory effects on bacterial growth [7]. The leaves of *S. arvensis* have antioxidant activity [8], as they contain several types of metabolites from the phenolic class, mainly flavonoids such as apigenin-7-O-glucoside, kaempferol, quercetin, rutin, coumarin, luteolin-7-O-glucoside, and phenolic acid (cinnamic acid, coumaric acid, and vanillic acid) [9].

Hypertension is one of the most common health problems during pregnancy and is estimated to be experienced by one in ten pregnant women [10-11]. This condition should be treated immediately because hypertension during pregnancy can lead to eclampsia and death of both mother and child [12]. It has been preclinically demonstrated that the leaves of *S. arvensis* and *A. cordifolia* have antihypertensive effects through several mechanisms, presumably mediated by different secondary metabolites. *S. arvensis* leaves have an antihypertensive effect by inducing diuresis [13], vasodilation of the aorta by promoting Nitric Oxide (NO) activity (ursolic acid and luteolin) [14], and inhibition of angiotensin-converting enzyme (ACE) activity (kaempferol and quercetin) [15]. *A. cordifolia* leaves have been shown to be involved in several pathways of antihypertensive activity, including aortic vasodilation through inhibition of calcium channel (apigenin), NO activity (oleanolic acid), β 1-adrenoreceptor antagonist (apigenin, vitexin, and isovitexin) [14, 16-17], and moderate ACE inhibition [18].

How to cite this article: Suliska N, Mentari SK, Sukandar EY. Evaluation of the teratogenic effect of water extract of *Sonchus arvensis* L. and *Anredera cordifolia* (Ten.) Steenis leaves as a combination in Wistar rat. J Res Pharm. 2023; 27(2): 762-768.

The ethanolic extract of *S. arvensis* and *A. cordifolia* in combination has been shown to have an antihypertensive effect by inhibiting ACE activity [19]. Meanwhile, the water extract of *S. arvensis* and *A. cordifolia* as a combination in a 1:1 ratio at a dose of 100 mg/kg body weight showed an effect to lower systolic and diastolic blood pressure by inhibiting adrenergic receptors [5], so it may be an additional option to treat hypertension in pregnant women. However, there is still no information on its teratogenic effects. Although the teratogenicity effects of the ethanolic extract of *S. arvensis* and *A. cordifolia* have been studied individually [20-21], and the content of secondary metabolites in water and in the ethanolic extract of *S. arvensis* and *A. cordifolia* are quite similar, a separate study should be conducted because the extract as a combination may have a different toxicity profile than the individual extract. Therefore, this research aims to evaluate the teratogenic effect of the water extract of *S. arvensis* and *A. cordifolia* leaves (WESAL) as a combination at a ratio of 1:1 in three doses.

2. RESULTS AND DISCUSSION

In each gestation period, female rats can give birth to 5-12 young, depending on the number of successful implantations that have occurred by the end of gestation. The weight of rat pups should be about 5-6 grams if born within the normal range of gestation period (21-23 days) [22]. As shown in Table 1, there was no significant difference in the average number and percentage of live fetuses per parent of all treatment groups compared to the control group, as well as the average weight of fetuses, which were all within the normal weight of rat fetuses removed from the uterus 1-2 days before birth, i.e., about 2-3 grams.

The resorption or undeveloped implant may occur most rapidly and spontaneously on the 7th day of gestation. It can occur earliest and spontaneously on the 7th day of pregnancy, i.e., it can also occur during pregnancy without any intervention [23-24]. These facts explain the occurrence of undeveloped fetuses in the control group. The number and percentage of resorptions were not inversely proportional to the administered dose of the extract, which was also found in a previous study on the teratogenic effect of ethanolic extract of *S. arvensis* and *A. cordifolia* individually [20-21]. Although the number and percentage of undeveloped fetuses in all treatment groups were not significantly different from the control group, this must be considered when determining the safety of the extract for pregnant women. Fetal deaths were not observed in all groups. Vertebral and skeletal limb evaluation is related to the bone ossification process that may happen later in some cases and affect the number of bones formed. This condition may result in abnormalities such as bend, cracked, and waved bone [25]. Therefore, it is essential to ensure that every dissection gets done simultaneously to prevent any bias during evaluation.

Rat vertebral consists of 7 cervical bones, 13 thoracic bones, which developed into ribs, 6 lumbar bones, and 4 sacral bones [26]. The skeletal limb consists of 5 distal phalanges bones and 4 proximal phalanges bones, 4 metacarpal bones at the forelimb and 5 metatarsal bones at the hindlimb. As shown in Table 2. and Table 3, there was no vertebral and skeletal limb malformation found in all groups, suggesting that *S. arvensis* and *A. cordifolia* extract as combination does not affect the skeletal development of the fetus (Figure 1).

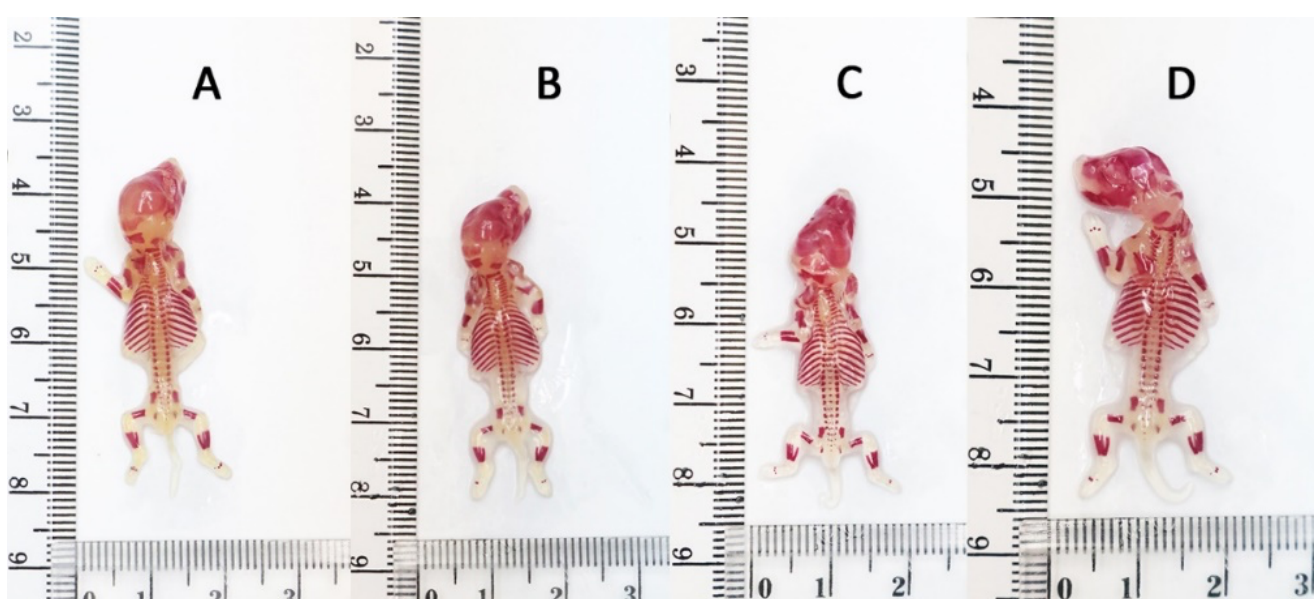


Figure 1. Normal skeleton (spine, ribs, forelimb, hindlimb) of (A) control, (B) WESAL 100 mg/kg bw, (C) WESAL 400 mg/kg bw, and (D) WESAL 1000 mg/kg bw group; WESAL : Water Extract of *Sonchus arvensis*-*Anredera cordifolia* Leaves

Organs of rat fetuses develop during gestational day 8 up to 13 [26-28]. Aside from organs inside the abdominal and thorax cavity, examination of organ malformation also involved the nose cavity, palate or upper jaw, and head cavity. Malformation of the nasal cavity may affect the respiratory system of the offspring, while malformation of the upper jaw indicated by split palate (cleft palate) later on may cause eating problems.

As shown in **Table 4**, there was no organ malformation among all observed fetuses, including the upper jaw, as shown in **Figure 2**. Otherwise, some fetuses with tiny brains were found in the control and treatment groups, ascending given doses of the extract with percentages of 3.89, 5.58, 4.01, and 7.83, respectively (**Figure 3**). Even though this incidence was also found in the control group and there was no significant difference between the percentage of this incidence in all treatment groups compared to the control group, this finding should be included in determining the extract's safety for pregnant women.

Table 1. Number of the alive and undeveloped fetus and fetal body weight

Groups	Alive fetus per parent		Undeveloped fetus (Resorption)		Fetus weight (gram)
	Σ	%	Σ	%	
Control	9.15±2.48	99.47±2.29	0.05±0.23	0.53±2.29	2.40±0.36
WESAL 100 mg/kg bw	7.60±2.41	99.57±1.81	0.06±0.24	0.43±1.81	2.39±0.25
WESAL 400 mg/kg bw	8.60±2.16	98.82±3.57	0.11±0.32	1.18±3.57	2.41±0.23
WESAL 1000 mg/kg bw	9.00±1.86	99.56±1.91	0.05±0.23	0.44±1.91	2.39±0.29

Data presented in average ± standard deviation (n=20); WESAL : Water Extract of *Sonchus arvensis*-*Anredera cordifolia* Leaves

Table 2. Examination of vertebral malformation

Groups	Σ total fetus	Σ observed fetus	Malformation (%)				
			Cervical	Thoracic	Lumbar	Sacral	Ribs
Control	183	66	0	0	0	0	0
WESAL 100 mg/kg bw	152	56	0	0	0	0	0
WESAL 400 mg/kg bw	172	65	0	0	0	0	0
WESAL 1000 mg/kg bw	180	66	0	0	0	0	0

WESAL : Water Extract of *Sonchus arvensis*-*Anredera cordifolia* Leaves

Table 3. Examination of skeletal limb malformation

Groups	Σ total fetus	Σ observed fetus	Malformation (%)					
			Forelimb			Hindlimb		
			DP	PP	Mc	DP	PP	Mt
Control	183	66	0	0	0	0	0	0
WESAL 100 mg/kg bw	152	56	0	0	0	0	0	0
WESAL 400 mg/kg bw	172	65	0	0	0	0	0	0
WESAL 1000 mg/kg bw	180	66	0	0	0	0	0	0

DP: distal phalanges; PP: proximal phalanges; Mc: metacarpal; Mt: metatarsal; WESAL : Water Extract of *Sonchus arvensis*-*Anredera cordifolia* Leaves

Table 4. Examination of organ malformation

Groups	Σ total fetus	Σ observed fetus	Malformation (%)											
			Hc	Ey	Uj	Hr	Lv	Kd	Tt/Ov	Ln	Fl	Hl	Tl	
Control	183	117	0	0	0	0	0	0	0	0	0	0	0	0
WESAL 100 mg/kg bw	152	96	0	0	0	0	0	0	0	0	0	0	0	0
WESAL 400 mg/kg bw	172	107	0	0	0	0	0	0	0	0	0	0	0	0
WESAL 1000 mg/kg bw	180	114	0	0	0	0	0	0	0	0	0	0	0	0

Hc: hydrocephalus; Ey: eye; Uj: upper jaw; Hr: heart; Lv: liver; Kd: kidney; Tt/Ov: testicles/ovary; Ln: lung; Fl: forelimb; Hl: hindlimb; Tl: tail; WESAL : Water Extract of *Sonchus arvensis*-*Anredera cordifolia* Leaves



Figure 2. Normal palate of the fetus of (A) control, (B) WESAL 100 mg/kg bw, (C) WESAL 400 mg/kg bw, and (D) WESAL 1000 mg/kg bw group; WESAL : Water Extract of *Sonchus arvensis*-*Anredera cordifolia* Leaves




Figure 2. Small brain of the fetus found in (A) control, (B) WESAL 100 mg/kg bw, (C) WESAL 400 mg/kg bw, and (D) WESAL 1000 mg/kg bw group; WESAL : Water Extract of *Sonchus arvensis*-*Anredera cordifolia* Leaves

3. CONCLUSION

The water extract of *S. arvensis* and *A. cordifolia* leaves as a combination at doses of 100 mg/kg body weight, 400 mg/kg body weight, and 1000 mg/kg body weight is contraindicated for pregnant women and those planning to become pregnant because of the finding of undeveloped fetuses (resorption) and some fetuses with small brains in the near future, although the percentage for these two conditions was not significantly different in each treatment group compared with the control group.

4. MATERIALS AND METHODS

4.1 Chemicals

Dry powder of water extract of *S. arvensis* and *A. cordifolia* leaves (PT. Phytochemindo Reksa, Indonesia), saline solution, alcohol (Merck®), glycerol (Merck®), formaldehyde 37% (Merck®), picric acid (Merck®), glacial acetic acid (Merck®), methylene blue powder (Merck®), Red Alizarin powder (Merck®), H₂O₂ solution 30% (Merck®), KOH granule (Merck®).

4.2 Apparatus

Microscope Olympus BX51

4.3 Methods

Methods used in this research were based on toxicity study guidelines for testing chemicals, and prenatal development regulation of the head of National Agency of Food And Drug Control Republic of Indonesia No. 7 (2014) adapted from OECD 414. All experimental animal protocols had been accepted by the Institutional Animal Ethics Committee (IAEC) with ethical approval number 16/KEPHP-ITB/12-2019.

4.3.1. Preparation of extract suspension

The mixture of water extract of *S. arvensis* and *A. cordifolia* leaves (WESAL) with ratio 1:1 made into suspension using Na-CMC 0,5% as a suspending agent.

4.3.2 Preparation of reagent solution

0,1% methylene blue solution for staining: 100 mg of methylene blue powder was dissolved into 100 ml aqua dest.

Bouin solution for visceral examination: formaldehyde, picric acid and glacial acetic acid were mixed inside the acid room with a ratio of 15:5:1, respectively.

0,5% KOH solution for skeletal examination: 5 g of KOH granule was dissolved into 1 L aqua dest.

1% H₂O₂ solution for skeletal examination: aquadest, 3 mL of H₂O₂ 30% solution was diluted up to 90 mL

Glycerol for skeletal examination: using aquadest, pure glycerol (100% glycerol) was diluted into 5 different concentrations: 5%, 20%, 40%, 60%, and 80%.

Alizarin Red solution for skeletal examination: Some alizarin red powder was diluted into KOH 0,5% solution. Make sure the solution does not get too thick or transparent to get good quality of skeletal staining.

4.3.3. Animal Pre-treatment

Animals were acclimated inside the cage with size 60 x 42 x 18 cm (l x w x h) at quarantine room of animal providing and care laboratory, School of Pharmacy, ITB. Wood crumbs were used as bedding and changed every 2-3 days. Water and solid food were given *ad libitum*. Room temperature and humidity were maintained at 25 ± 2°C and 65 ± 10%, respectively.

4.3.4. Mating Process and Determination of Early Pregnancy

Once reached its oestrous period, female Wistar rats (weight 150-200 g; age 8-12 weeks) were placed at the same cage with sexually matured male Wistar rats (weight 250-300 g; age 8-12 weeks) with ratio 4 female rats to 1 male rat at late afternoon. The following day, in the early morning, male Wistar rats were moved to different cages. A small pipette tip was used for pipetting the saline solution and then was flushed into the vaginal hole of the female rat. A thin smear was made by dripping saline contained cell suspension on a slide. After the smear got dry, it was stained with 0.1% methylene blue then examined under a microscope with a magnification of 400x [20-21]. Early pregnancy was determined by the presence of sperm cells in vaginal smear and documented as day 0 or G0 (short for gestational day 0).

4.3.5. Extract Administration

Pregnant rats were distributed into 4 groups which consisted of the control group and three treatment groups. The control group was given Na-CMC 0.5% orally as much as 1 mL/100 g bw while treatment groups were given water extract of *S. arvensis* and *A. cordifolia* leaves (WESAL) as a combination at doses of 100, 400, and 1000 mg/kg bw started from gestational day 6 up to 15.

4.3.6. Termination and Observation

On gestational day 19 (G19), pregnant rats were sacrificed by putting them inside a CO₂ chamber. The abdominal part of the rats was dissected. All fetuses were taken out from the uterus, then cleaned, dried, and weighted individually. Incidence of the undeveloped fetus (resorption) was noted and documented. Two-third number of the alive fetuses were fixed in Bouin solution for visceral examination. In contrast, one-third of the rest were fixed in 90% alcohol solution for skeletal analysis for at least 1-2 weeks.

4.3.7. Skeletal Preservation

Preparation: After the fixation process, the fetus was skinned completely. The abdominal wall was cut, and all internal organs were taken out. Eyes and fat around the body were removed, then legs and underarm parts were cut out of the body.

Cleaning: Fetuses were washed out in running water then soaked into 0,5% KOH solution for several days until no remaining skin and fat were attached to the body.

Bleaching: Fetuses were washed out in running water, dried, then soaked into 1% H₂O₂ solution for 2-3 hours or until all skeletal got white.

Staining: Fetuses were washed in running water, dried, then soaked into an alizarin red solution for 24 hours at most. At the moment, all skeletal should be seen clearly.

Final cleaning: After staining was considered perfectly done, fetuses were washed out then gradually immersed in 5%, 20%, 40%, 80% glycerol solution, respectively and lastly, pure glycerol for 1 week each [20-21].

4.3.8. Skeletal Evaluation

The skeletal evaluation included posterior parts such as the skull, spine, and ribs and anterior parts such as bone around the shoulder, hip, forelimb, and hind limb. Finding skeletal malformation such as decreasing bone, broken part of the bone, and misplaced bone was recorded and documented.

4.3.9. Visceral Evaluation

After the fixation process, fetuses were collected in a beaker glass full of water. Fetuses were cleaned and dried. The part between the head and the body was cut using a surgical blade. The cross-section was made between the upper and lower jaw to examine the palate, middle-upper head part to examine the brain, and around 1 cm behind the nosetip to examine the olfactory cavity. The abdominal wall was cut, and all organs were taken out. The presence, size, and colour of the organs (liver, heart, lung, kidney, and genital parts) were examined. Any abnormality was recorded and documented [20-21].

5.2.10. Data Analysis

Data were analyzed with one-way ANOVA followed by LSD post hoc analysis using IBM SPSS 28. $P < 0.05$ was considered significantly different.

Acknowledgements: We would like to thank the Education Fund Management Institute (LPDP), the Innovative Research Productive Invitations of Educational Fund Management Institutions (RISPRO Invitasi LPDP), for funding this research. Thank you to the Faculty of Pharmacy ITB for all facilities for this research.

Author contributions: Concept - E.Y.S.; Design - E.Y.S., N.S.; Supervision - E.Y.S., N.S.; Resources - E.Y.S.; Materials - E.Y.S.; Data Collection and/or Processing - S.K.M.; Analysis and/or Interpretation - E.Y.S., N.S., S.K.M.; Literature Search - E.Y.S., N.S., S.K.M.; Writing - S.K.M.; Critical Reviews - E.Y.S., N.S.

Conflict of interest statement: The authors declared no conflict of interest.

REFERENCES

- [1] Salim Z, Munadi E, Info Komoditi Tanaman Obat, Badan Pengkajian dan Pengembangan Perdagangan Kementerian Perdagangan Republik Indonesia, Indonesia, 2017.
- [2] Sukandar EY, Ayuningtyas DK. *Anredera cordifolia* (Ten.) Steenis: A New Emerging Cure with Polypharmacological Effect, in Ghost D, Mukherjee PK, ed; *Natural Medicines: Clinical Efficacy, Safety and Quality*, CRC Press Taylor & Francis Group, Florida.
- [3] Dhianawaty D, Soediro I, Soemardji A. Two synergetic effects of *Sonchus arvensis* L. leaves decoction in calcium oxalate bladder stone therapy on male Wistar rat. 2012; 2(2): 147-9.
- [4] Yuan T, Wu D, Sun K, Tan X, Wang J, Zhao T, Ren B, Zhao B, Liu Z, Liu, X. Anti-fatigue activity of aqueous extracts of *sonchus arvensis* L. In exercise trained mice. *Molecules*. 2019; 24(6): 5-7. [CrossRef]
- [5] Suliska N, Suryani, Insanu M, Sukandar EY. Antihypertensive activity of combination of *anredera cordifolia* (Ten.) V. Steenis and *Sonchus arvensis* L. leaves on Epinephrine Induced male Wistar Rat. *J Adv Pharm Technol Res*. 2021; 12(4): 384-8. [CrossRef]
- [6] Sukandar EY, Kurniati NF, Nurdianti AF. Antiobesity effect of ethanol extract of *anredera cordifolia* (ten) steenis leaves on obese male wistar rats induced by a high-carbohydrate diet. *Int J Pharm Pharm Sci*. 2016; 8(4): 171-3.

- [7] Basyuni M and Lesmana I. Phytochemical analysis of Binahong (*Anredera cordifolia*) leaves extract inhibit In Vitro growth of *Aeromonas Hydrophila*. AIP Publishing. 2017; 1-5.
- [8] Chairul SM, Sumarny R, Chairul. Aktivitas antioksidan ekstrak air daun tempuyung (*Sonchus arvensis* L.) secara in-vitro. Majalah Farmasi Indonesia. 2003; 14(4): 208-15.
- [9] Khuluk RH, Yunita A, Rohaeti E, Syafitri UD, Linda R, Lim LW, Takeuchi T, Rafi M. An HPLC-DAD Method to Quantify Flavonoids in *Sonchus arvensis* and Able to Classify the Plant Parts and Their Geographical Area through Principal Component Analysis. Separations. 2021; 8(2): 1-10. [CrossRef]
- [10] National High Blood Pressure Education Program Working Group, High blood pressure in pregnancy, 2000.
- [11] Podymow T, August P. Antihypertensive Drugs in Pregnancy. Seminars in Nephrology. 2011; 31(1): 70-85. [CrossRef]
- [12] Samadi A, Mayberry R, Zaidi A, Pleasant J, McGhee M, Rice R. Maternal hypertension and associated pregnancy complications among AfricanAmerican and other women in the United States. Obstet Gynecol. 1996; 87: 557-63. [CrossRef]
- [13] Muhtadi, Wahyuningtyas N, Sutrisna EM, Suhendi A, Anggoro BKS. Efek Diuresis Dari Kombinasi Ekstrak Salam (*Syzygium polyanthum* Wight.) dan Tempuyung (*Sonchus arvensis* L.) pada Mencit Hiperurisemia. 4th Univ Res Coloquium 2016. 2016; 22-7.
- [14] Sukandar EY, Ridwan A, Sukmawan YP, Vasodilatation effect of ethanolic extract of *Anredera cordifolia*, *Sonchus arvensis* L, and ursolic acid on isolated rabbit aortic and frog heart. Int J Pharm Pharm Sci. 2016; 8(2): 145-9.
- [15] Suryani, Sukandar EY, Sutjiatmo AB, Vikasari SN. Angiotensin Converting Enzyme Inhibitor Activity of Ethanol Extract of *Sonchus Arvensis* (Linn.) Leaves. In: The 6th International Conference. 2017. p. 124-128.
- [16] Sukandar EY, Ridwan A, Sukmawan TP, Vasodilation effect of oleanolic acid and apigenin as a metabolite compound of *Anredera cordifolia* (Ten) V Steenis on isolated rabbit aortic and frog heart. Int.J.Res Ayurveda Pharm. 2016; 7(5): 82-4. [CrossRef]
- [17] Garmana AN, Sukandar EY, Fidrianny I . Preliminary study of blood pressure-lowering effect of *anredera cordifolia* (ten.) steenis) on Wistar rats. IJPPR. 2016; 8(2): 300-30.
- [18] Vasant OK, Vijay BG, Virbhadrappa SR, Dilip NT, Ramahari MV, Laxamanrao BS. Antihypertensive and diuretic effects of the aqueous extract of *Colocasia esculenta* Linn. leaves in experimental paradigms. Iran J Pharm Res 2012; 11: 621-34.
- [19] Sukandar EY, Garmana, AN, Aidasari AU , Crystalia AA. Antihypertensive activity of ethanol extract combination of *Anredera cordifolia* (Ten.) v. Steenis and *Sonchus arvensis* L. leaves on angiotensin II- induced male wistar rat. J Res Pharm. 2019; 23(6): 1090-97. [CrossRef]
- [20] Sukandar EY, Safitri D, Evaluation of Teratogenic Effect of Tempuyung (*Sonchus arvensis*) Extract on Wistar Rats. IJPPR. 2016; 8(5): 761-6.
- [21] Sukandar EY, Kurniati NF, Ftria V. Evaluation of teratogenicity effects of ethanolic extracts of binahong leaves (*Anredera cordifolia* (Ten.) Steenis in wistar rat. Int J Parm Pharm Sci. 2014; 6(11): 422-6.
- [22] John Hopkins Univerisity. <https://web.jhu.edu/animalcare/procedures/rat.html> (accessed on 25 August 2021)
- [23] Chahoud I, Franklin CB. Relationships between fetal body weight of Wistar rats at term and the extent of skeletal ossification. Braz J Med Biol Res. 2005; 38: 565-75. [CrossRef]
- [24] Drews B, Landaverde LF, Kühl A, Drews U. Spontaneous embryo resorption in the mouse is triggered by embryonic apoptosis followed by rapid removal via maternal sterile purulent inflammation. BMC Dev Biol. 2020; 20(1): 1-18. [CrossRef]
- [25] Dwornik JJ, Moore KL. Skeletal Malformations in the Holtzman Rat Embryo Following the Administration of Thalidomide. J Embryol Exp Morphol. 1965; 13(2): 181-93.
- [26] Fadel RA, Sequeira RP, Abu-Hijleh MF, Obeidat M, Salem AHA. Effect of prenatal administration of therapeutic doses of topiramate on ossification of ribs and vertebrae in rat fetuses. Rom J Morphol Embryol. 2012; 53(2): 321-7.
- [27] Hill M. Mouse Timeline Detailed. embryology.med.unsw.edu.au/embryology/index.php/Mouse_Timeline_Detailed (accessed 3 February 2021)
- [28] Otis E, Brent R. Equivalent ages in mouse and human embryos. Anat Rec. 1954; 120(1): 33-63.
- [28] Seely J. A Brief Review of Kidney Development, Maturation, Developmental Abnormalities, and Drug Toxicity: Juvenile Animal Relevancy. J Toxicol Pathol. 2017; 30(2): 125-33. [CrossRef]